

151468

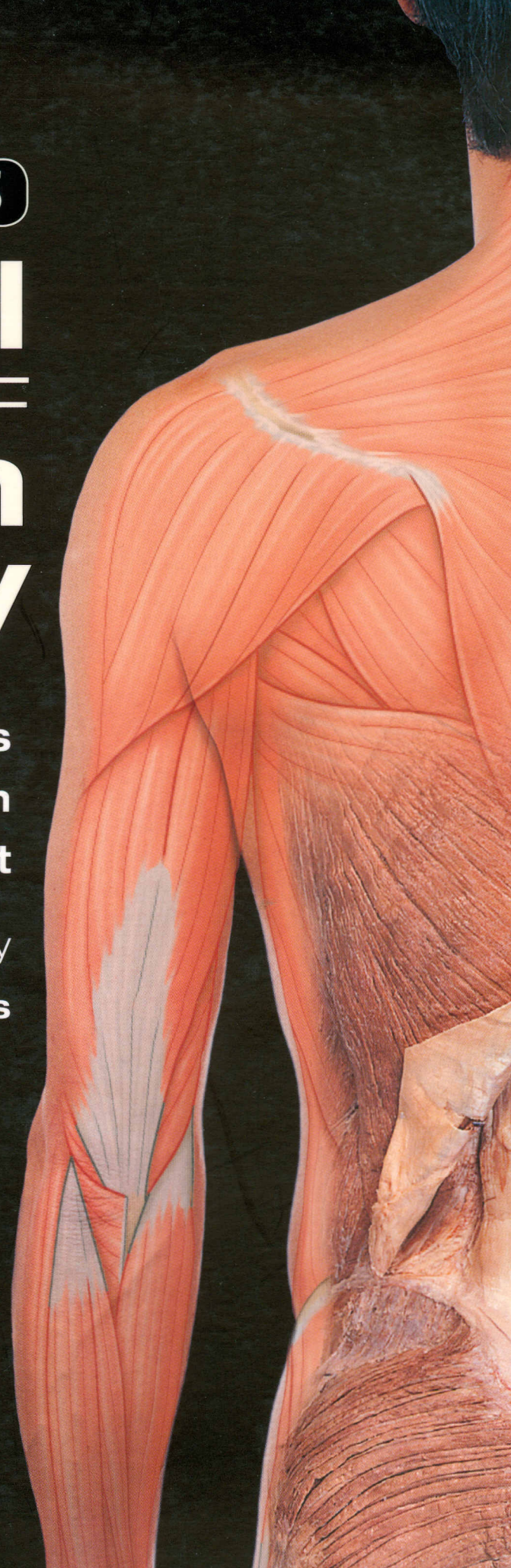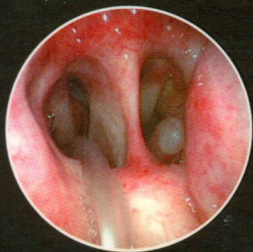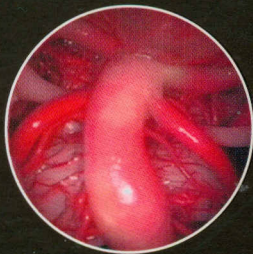
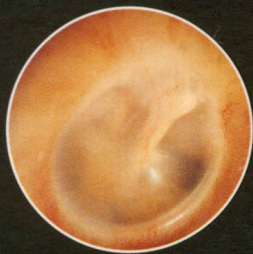SIXTH EDITION

McMINN'S

Clinical ATLAS OF Human Anatomy

**Peter H. Abrahams
Johannes M. Boon
Jonathan D. Spratt**

Photography by
Ralph T. Hutchings



**Includes DVD
OF 1000
Clinical Cases!**

MOSBY
ELSEVIER

Contents

Dedication	vii
Preface	viii
Acknowledgements	ix
User guide	xi
Orientation	xii

Systemic review

1

Skeleton	1
Muscles	2
Arteries	4
Veins	4
Nerves	5
Dermatomes	6
Cross-sections of the human body	7

Head, neck and brain

2

Skull	11
Skull bones	28
Neck	38
Root of neck	46
Face	48
Temporal and infratemporal fossa	50
Pharynx	55
Larynx	58
Cranial cavity	61
Eye	64
Nose	68
Nose and Tongue	69
Ear	70
Brain	72
Cranial nerves	83
Clinical thumbnails	90–92

Vertebral column and spinal cord

3

Vertebral column overview	93
Back and shoulder	94
Vertebrae	95
Sacrum	99
Sacrum and coccyx	100
Bony pelvis	102
Vertebral ossification	103
Vertebral column and spinal cord	104
Surface anatomy of the back	110
Muscles of back	111
Vertebral radiographs	114
Clinical thumbnails	116

Upper limb

4

Upper limb overview	117
Upper limb bones	118
Shoulder	134
Axilla	144
Arm	147
Elbow	149
Forearm	152
Hand	158
Wrist and hand radiographs	173
Clinical thumbnails	174–176

Thorax

5

Thorax overview	177
Thoracic bones	178
Thoracic wall surface markings and breast	182
Breast	183
Thoracic wall	185
Thoracic viscera	188
Heart	189
Mediastinum	196
Mediastinal imaging	200
Lungs	201
Superior mediastinum	209
Superior mediastinum and thoracic inlet	210
Superior thoracic aperture (thoracic inlet)	211
Posterior mediastinum	213
Intercostal nerves and thoracic joints	215
Aorta and associated vessels	216
Diaphragm	217
Oesophageal imaging	218
Clinical thumbnails	219–220

Abdomen and pelvis

6

Abdomen overview	221
Anterior abdominal wall	222
Female inguinal region	229
Upper abdomen	230
Intestinal imaging	241
Liver	245
Spleen	250
Spleen and intestines	251
Intestines	252
Small intestine	253
Kidneys and suprarenal glands	254
Diaphragm and posterior abdominal wall	261
Posterior abdominal and pelvic walls	262
Pelvic walls	264
Male inguinal region, external genitalia	266
Male pelvis	267
Pelvic vessels and nerves	271
Pelvic ligaments	273
Female pelvis	274
Female perineum	278
Male perineum	279
Clinical thumbnails	281–284

Lower Limb

7

Lower limb preview	285
Lower limb bones	286
Foot bones	310
Development of lower limb bones	314
Gluteal region	316
Thigh	318
Front of thigh	320
Hip joint	324
Knee	328
Knee radiographs	336
Leg	337
Ankle and foot	344
Foot	350
Ankle and foot imaging	354
Clinical thumbnails	355–357

Lymphatics

8

Lymphatic system	358
Lymphangiography	358
Thymus	359
Chest	359
Palatine tonsils	359
Neck	360
Thoracic duct	360
Right axilla	361
Cisterna chyli and thoracic duct	361
Female pelvis	363
Thigh and superficial inguinal lymph nodes	365
Clinical thumbnails	366
Index	367