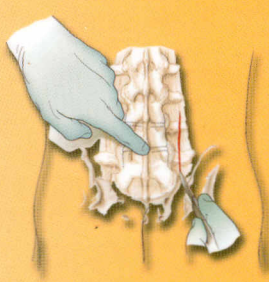
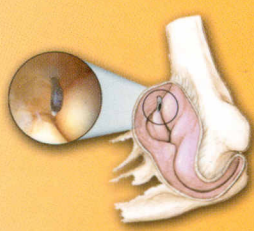
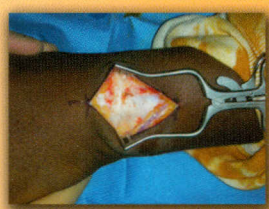
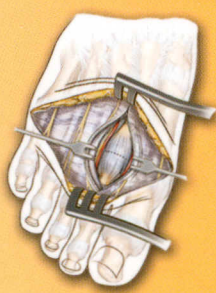
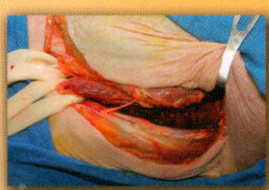
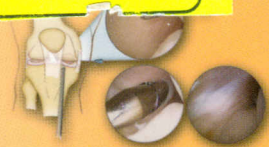151886




# ORTHOPAEDIC SURGICAL APPROACHES

Miller • Chhabra • Hurwitz • Mihalko • Shen



SAUNDERS  
ELSEVIER



# Contents

## CHAPTER 1

### INTRODUCTION: APPROACH TO THE SURGICAL PATIENT 1

- Regional Anatomy 3
- Cross-sectional Anatomy 5
- Topographical Landmarks 5
- Hazards 5

## CHAPTER 2

### SHOULDER AND ARM 7

- Regional Anatomy 8
- Cross-sectional Anatomy 19
- Landmarks 20
- Hazards 21
- Surgical Approaches to the Shoulder and Arm
  - Anterior (Deltopectoral) Approach to the Shoulder 23
  - Posterior Approach to the Shoulder 30
  - Superolateral Approach to the Shoulder 34
  - Lateral (Deltoid Splitting [Mini-Open]) Approach to the Shoulder 38
  - Approach to the AC Joint 41
  - Superior Approach to the Supraspinatus Fossa 44
  - Approach to the Clavicle 46
  - Anterior Approach to the Humerus 49
  - Posterior Approach to the Humerus 51
  - Shoulder Arthroscopy 54

## CHAPTER 3

### ELBOW AND FOREARM 61

- Regional Anatomy 62
- Cross-Sectional Anatomy 82
- Hazards 84
- Surgical Approaches to the Elbow and Forearm
  - Anterior Approach to Elbow (Antecubital Fossa) 85
  - Medial Approach to Elbow and Humerus 91
  - Kocher Approach (Lateral Elbow) 97
  - Bryan-Morrey Approach (Triceps Sparing Approach) 102
  - Triceps Splitting Approach 108
  - Olecranon Osteotomy 112
  - Elbow Arthroscopy 115
  - Henry Approach (Volar Approach to Forearm) 124
  - Thompson Approach (Dorsal Approach to Forearm) 130
  - Approach to Ulnar Shaft 136
  - Forearm Compartment Release 139

## CHAPTER 4

### WRIST AND HAND 145

- Regional Anatomy 146
- Hazards 160
- Surgical Approaches to the Wrist and Hand
  - Dorsal Approach to the Forearm, Wrist, and Carpus 164
  - Volar (Henry) Approach to Wrist 169
  - Exposure of the Median Nerve in the Palm and Distal Aspect of the Forearm 176
  - Approach to the Ulnar Nerve and Artery in the Distal Forearm and Palm 181
  - Approach to Apply an External Fixator for the Wrist 185
  - Wrist Arthroscopy 188
  - Dorsal Approach to Metacarpals 194
  - Dorsal Approach to Fingers 197
  - Volar Approach to the Finger 200
  - Midlateral Approach to Fingers 203
  - Approach for Finger Infections 205
  - Approach for Compartment Release in the Hand 208

## CHAPTER 5

### SPINE 211

- Regional Anatomy 212
- Cross-Sectional Anatomy 228
- Landmarks 230
- Surgical Approaches to the Cervical Spine
  - Anterior Approach to the Cervical Spine 232
  - Anterior Transthoracic Approach to Thoracic Spine 242
  - Anterior Thoracoabdominal Approach to the Thoracic and Lumbar Spine 253
  - Anterior Retroperitoneal Approach to the Lumbar Spine 261
  - Anterior Transperitoneal Approach to the Lumbosacral Spine 269
  - Posterior Approach to the Occipitocervical Junction (O-C2) 276
  - Posterior Approach to the Subaxial Cervical Spine and Cervicothoracic Junction 283
  - Posterior Midline Approach to the Thoracic Spine 290
  - Posterior Extracavitary/Costotransversectomy/Posterolateral Approach to the Thoracic Spine 296

Posterior Midline Approach to Lumbar Spine	304
Posterior Muscle Splitting Approach to the Lumbar Spine	315
Anterior Iliac Crest Bone Graft	320
Posterior Iliac Crest Bone Graft	325

## CHAPTER 6

### HIP AND PELVIS 331

Regional Anatomy	332
Cross-Sectional Anatomy	348
Hazards	352
Landmarks	354
Surgical Approaches to the Pelvis	
Posterior Approach to the Sacroiliac Joint	355
Anterior Approach to the Pubic Symphysis	358
Ilioinguinal Approach to the Pelvis	362
Posterior Approach to the Acetabulum (Kocher-Langenbach)	368
Surgical Approaches to the Hip	
Anterior Approach to the Hip (Smith-Petersen)	375
Posterior Approach to the Hip	382
Medial Approach to the Hip	390
Lateral Approach to the Hip	395
Anterolateral Approach to the Hip	402
Two Incision Hip MIS Approach	410
Hip Arthroscopy	415

## CHAPTER 7

### KNEE AND LOWER LEG 423

Regional Anatomy	424
Cross-Sectional Anatomy	436
Landmarks	438
Hazards	439
Surgical Approaches to the Knee and Leg	
Anterior Approaches to the Knee	441
Inferomedial Approach for Hamstring Harvest	449
Medial Approach to the Knee	452
Lateral Approach to the Knee	457
Posterior Approach to the Knee	462
Lateral Approach to the Proximal Tibia	470
Medial Approach to the Proximal Tibia	474
Lateral Approach to the Leg	477
Medial Approach to the Leg	480
Knee Arthroscopy	483

## CHAPTER 8

### FOOT AND ANKLE 491

Regional Anatomy	492
Cross-Sectional Anatomy	516
Hazards	518
Surgical Approaches to the Foot and Ankle	
Anterior Approach to the Ankle	520
Approach to the Medial Malleolus	523
Approach to the Medial Side of Ankle	527
Approach to the Tarsal Tunnel	530
Posteromedial Approach to the Ankle	532
Approach to the Achilles Tendon	535
Posterolateral Approach to the Ankle	538
Approach to the Lateral Malleolus	542
Anterolateral Approach to the Ankle	545
Anterolateral Approach to the Hind Foot	548
Approach to the Tibialis Posterior Tendon	551
Extensile Lateral Approach to the Calcaneus	553
Anterolateral Approach to Talus Neck	556
Dorsomedial Approach to Talus Neck	558
Anterolateral Approach for Subtalar Dislocation	560
Extensile Dorsomedial Exposure to the Midfoot	562
Dorsal Approach to the First and Second Metatarsal	565
Approach for Phalangeal Dislocation	568
Dorsal and Dorsomedial Approach to the First MTP Joint	570
Medial Approach to the First MTP Joint	574
Dorsal Approach to the MTP Joints of the 2nd-5th Toes with Proximal Interphalangeal Joint Exposure	576
Lateral Approach to the 5th MTP Joint	580
Approach to the Dorsal Web Space	582
Dorsal Approach to the Metatarsal Heads	585
Approach for Sesamoid Fracture	588

## INDEX 591