

151434

Müller • Silva

Imaging of the Chest

Volume I

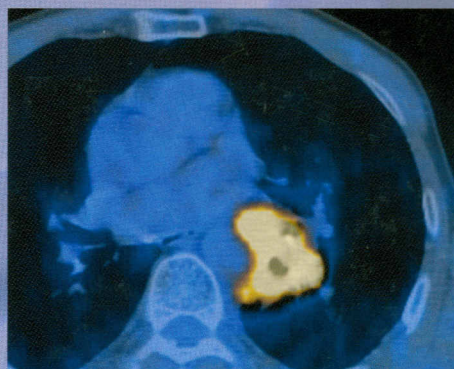
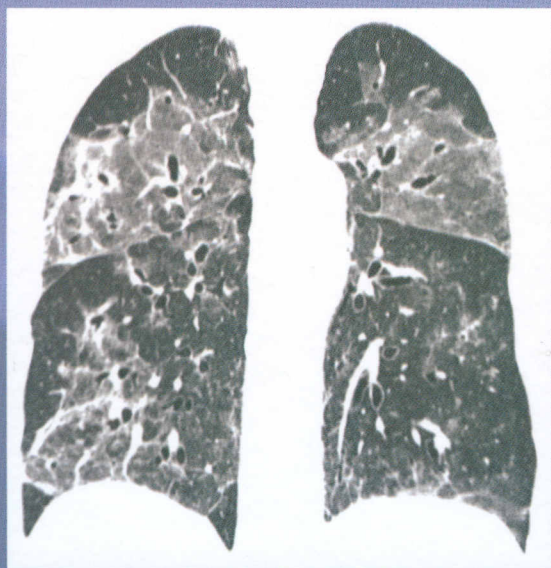
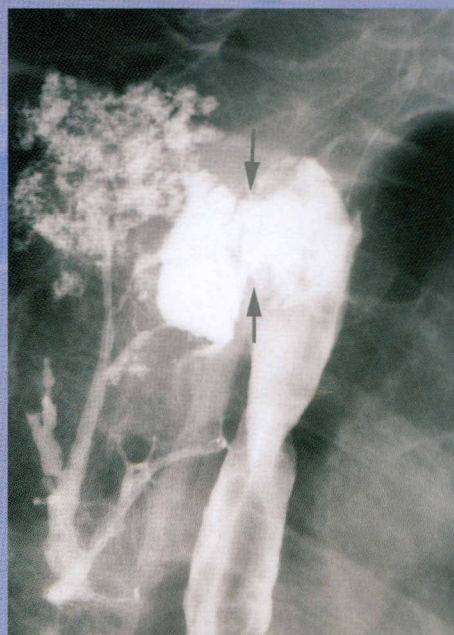
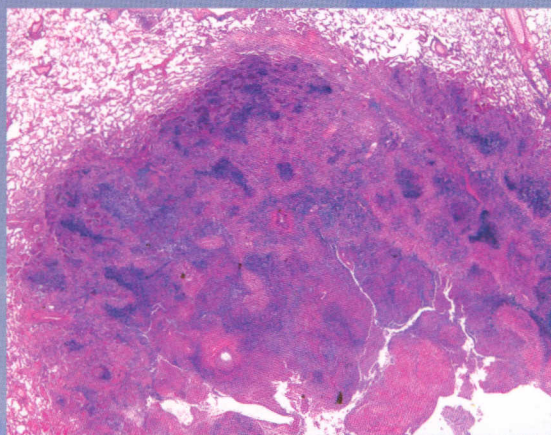


Table of Contents

Volume I

PART ONE: NORMAL CHEST

CHAPTER 1 **Normal Chest Radiograph** 3
Nestor L. Müller and C. Isabela S. Silva

CHAPTER 2 **Normal Computed Tomography of the Chest** 34
Nestor L. Müller and C. Isabela S. Silva

CHAPTER 3 **Ultrastructure of the Pulmonary Parenchyma** 81
Harumi Itoh and Nestor L. Müller

PART TWO: RADIOLOGIC MANIFESTATIONS OF LUNG DISEASE

CHAPTER 4 **Consolidation** 97
Nestor L. Müller and C. Isabela S. Silva

CHAPTER 5 **Atelectasis** 116
Nestor L. Müller and C. Isabela S. Silva

CHAPTER 6 **Nodules and Masses** 136
Nestor L. Müller and C. Isabela S. Silva

CHAPTER 7 **Interstitial Patterns** 158
Nestor L. Müller and C. Isabela S. Silva

CHAPTER 8 **Decreased Lung Density** 200
Nestor L. Müller and C. Isabela S. Silva

PART THREE: DEVELOPMENTAL LUNG DISEASE

CHAPTER 9 **Airway and Parenchymal Anomalies** 213
Nestor L. Müller and C. Isabela S. Silva

CHAPTER 10 **Congenital Malformations of the Pulmonary Vessels in Adults** 232
Jacques Remy, John F. Bruzzi, and Martine Remy-Jardin

PART FOUR: PULMONARY INFECTION

CHAPTER 11 **Community-Acquired Pneumonia** 267
Tomás Franquet and Christian J. Herold

CHAPTER 12 **Bacterial Pneumonia** 290
Nestor L. Müller and C. Isabela S. Silva

CHAPTER 13 **Pulmonary Tuberculosis** 322
Kyung Soo Lee

CHAPTER 14 **Nontuberculous (Atypical) Mycobacterial Infection** 342
David M. Hansell

CHAPTER 15 **Fungal Infections** 356
Rebecca M. Lindell and Thomas E. Hartman

CHAPTER 16 **Mycoplasma Pneumoniae** 381
Nestor L. Müller and C. Isabela S. Silva

CHAPTER 17 **Chlamydia** 386
Nestor L. Müller and C. Isabela S. Silva

CHAPTER 18 **Viruses** 391
Nestor L. Müller and C. Isabela S. Silva

CHAPTER 19 **Parasites** 408
Nestor L. Müller and C. Isabela S. Silva

PART FIVE: THE IMMUNOCOMPROMISED PATIENT

CHAPTER 20 **Acquired Immunodeficiency Syndrome (AIDS)** 425
Joel E. Fishman, Galit Aviram, and Ahuva Grubstein

CHAPTER 21 **Immunocompromised Host (Non-AIDS)** 454
Ann Leung

PART SIX: PULMONARY NEOPLASMS

CHAPTER 22 **Lung Cancer: Overview and Classification** 469
William D. Travis

CHAPTER **23 Screening for Lung Cancer** 487
Thomas E. Hartman

CHAPTER **24 Lung Cancer: Radiologic Manifestations and Diagnosis** 494
Jeffrey S. Klein and Anthony Febles

CHAPTER **25 Pulmonary Carcinoma: Staging** 517
Kyung Soo Lee

CHAPTER **26 Carcinoid Tumors, Pulmonary Tumorlets, and Neuroendocrine Hyperplasia** 542
Nestor L. Müller and C. Isabela S. Silva

CHAPTER **27 Neoplasms of Tracheobronchial Glands** 553
Nestor L. Müller and C. Isabela S. Silva

CHAPTER **28 Pulmonary Hamartoma** 559
Nestor L. Müller and C. Isabela S. Silva

CHAPTER **29 Inflammatory Pseudotumor** 564
Nestor L. Müller and C. Isabela S. Silva

CHAPTER **30 Pulmonary Metastases** 568
Nestor L. Müller and C. Isabela S. Silva

PART SEVEN: LYMPHOPROLIFERATIVE DISORDERS AND LEUKEMIA

CHAPTER **31 Pulmonary Lymphoid Hyperplasia and Lymphoid Interstitial Pneumonia (Lymphocytic Interstitial Pneumonia)** 585
C. Isabela S. Silva and Nestor L. Müller

CHAPTER **32 Non-Hodgkin's Lymphoma** 595
Kyung Soo Lee

CHAPTER **33 Hodgkin's Disease** 616
Kyung Soo Lee

PART EIGHT: INTERSTITIAL LUNG DISEASE

CHAPTER **34 Idiopathic Pulmonary Fibrosis** 629
Nestor L. Müller and C. Isabela S. Silva

CHAPTER **35 Nonspecific Interstitial Pneumonia** 644
Nestor L. Müller and C. Isabela S. Silva

CHAPTER **36 Cryptogenic Organizing Pneumonia (Bronchiolitis Obliterans Organizing Pneumonia)** 655
Nestor L. Müller and C. Isabela S. Silva

CHAPTER **37 Acute Interstitial Pneumonia** 663
Nestor L. Müller and C. Isabela S. Silva

CHAPTER **38 Sarcoidosis** 668
Nestor L. Müller and C. Isabela S. Silva

CHAPTER **39 Hypersensitivity Pneumonitis** 689
C. Isabela S. Silva and Nestor L. Müller

CHAPTER **40 Pulmonary Langerhans Cell Histiocytosis** 708
Susan J. Copley

CHAPTER **41 Smoking-Related Interstitial Lung Disease** 718
Susan J. Copley

CHAPTER **42 Lymphangioleiomyomatosis and Tuberos Sclerosis** 730
Nicola Sverzellati and David M. Hansell

PART NINE: CONNECTIVE TISSUE DISEASES

CHAPTER **43 Rheumatoid Arthritis** 745
Maureen Quigley and David M. Hansell

CHAPTER **44 Systemic Sclerosis (Scleroderma)** 759
Maureen Quigley and David M. Hansell

CHAPTER **45 Systemic Lupus Erythematosus** 766
Maureen Quigley and David M. Hansell

CHAPTER **46 Polymyositis/Dermatomyositis** 776
Maureen Quigley and David M. Hansell

CHAPTER **47 Sjögren's Syndrome** 785
Maureen Quigley and David M. Hansell

CHAPTER **48 Mixed Connective Tissue Disease** 795
Maureen Quigley and David M. Hansell

CHAPTER **49 Relapsing Polychondritis** 801
Maureen Quigley and David M. Hansell

Volume II

PART TEN: VASCULITIS AND GRANULOMATOSIS

CHAPTER **50 Wegener Granulomatosis** 811
Nestor L. Müller and C. Isabela S. Silva

CHAPTER **51 Churg-Strauss Syndrome** 821
C. Isabela S. Silva and Nestor L. Müller

CHAPTER **52 Goodpasture Syndrome (Anti-Basement Membrane Antibody Disease)** 828
Nestor L. Müller and C. Isabela S. Silva

CHAPTER **53 Microscopic Polyangiitis** 834
Nestor L. Müller and C. Isabela S. Silva

CHAPTER **54 Behçet's Disease** 839
Nestor L. Müller and C. Isabela S. Silva

CHAPTER **55 Takayasu Arteritis** 845
Nestor L. Müller and C. Isabela S. Silva

PART ELEVEN: EOSINOPHILIC LUNG DISEASES

CHAPTER 56 **Simple Pulmonary Eosinophilia (Löffler Syndrome)** 853

Takeshi Johkoh

CHAPTER 57 **Chronic Eosinophilic Pneumonia** 856

Takeshi Johkoh

CHAPTER 58 **Acute Eosinophilic Pneumonia and Hypereosinophilic Syndrome** 862

Takeshi Johkoh

PART TWELVE: METABOLIC LUNG DISEASES

CHAPTER 59 **Metabolic and Storage Lung Diseases** 869

Nestor L. Müller and C. Isabela S. Silva

PART THIRTEEN: PULMONARY EMBOLISM, HYPERTENSION, AND EDEMA

CHAPTER 60 **Acute Pulmonary Embolism** 889

Martine Remy-Jardin and Jacques Remy

CHAPTER 61 **Chronic Pulmonary Thromboembolism** 907

Martine Remy-Jardin and Jacques Remy

CHAPTER 62 **Nonthrombotic Pulmonary Embolism** 921

Nestor L. Müller and C. Isabela S. Silva

CHAPTER 63 **Pulmonary Arterial Hypertension** 936

Nicholas J. Screatton and Deepa Gopalan

CHAPTER 64 **Permeability Pulmonary Edema** 964

Kazyua Ichikado

CHAPTER 65 **Hydrostatic Pulmonary Edema** 978

Nestor L. Müller and C. Isabela S. Silva

PART FOURTEEN: DISEASES OF THE AIRWAYS

CHAPTER 66 **Tracheal Abnormalities: Tracheal Stenosis** 995

Maryellen Sun and Phillip M. Boiselle

CHAPTER 67 **Tracheal Abnormalities: Tracheal Neoplasms** 999

Karen S. Lee and Phillip M. Boiselle

CHAPTER 68 **Tracheal Abnormalities: Tracheomalacia** 1005

Phillip M. Boiselle

CHAPTER 69 **Tracheal Abnormalities: Relapsing Polychondritis** 1009

Phillip M. Boiselle

CHAPTER 70 **Tracheal Abnormalities: Tracheomegaly** 1014

Phillip M. Boiselle

CHAPTER 71 **Tracheal Abnormalities: Tracheobronchopathia Osteochondroplastica** 1018
Phillip M. Boiselle

CHAPTER 72 **Bronchial Abnormalities** 1021
Sujal R. Desai

CHAPTER 73 **Specific Causes of Bronchiectasis** 1039
Nestor L. Müller and C. Isabela S. Silva

CHAPTER 74 **Asthma** 1056
C. Isabela S. Silva and Nestor L. Müller

CHAPTER 75 **Bronchiolitis** 1071
C. Isabela S. Silva and Nestor L. Müller

CHAPTER 76 **Emphysema** 1096
Alexander A. Bankier

PART FIFTEEN: INHALATIONAL DISEASES AND ASPIRATION

CHAPTER 77 **Silicosis and Coal Workers' Pneumoconiosis** 1117

Clara G. Ooi

CHAPTER 78 **Asbestos-Related Disease** 1140

C. Isabela S. Silva and Nestor L. Müller

CHAPTER 79 **Uncommon Pneumoconioses** 1167
Masanori Akira

CHAPTER 80 **Aspiration** 1182
Tomás Franquet

PART SIXTEEN: IATROGENIC LUNG DISEASE AND TRAUMA

CHAPTER 81 **Drug-Induced Lung Disease** 1201
C. Isabela S. Silva and Nestor L. Müller

CHAPTER 82 **Radiation-Induced Lung Disease** 1225
Jeremy J. Erasmus, M. Kara Bucci, and Reginald F. Munden

CHAPTER 83 **Blunt Thoracic Trauma** 1241
Nicholas J. Statkus, Joshua R. Hill, Marc V. Gosselin, and Steven L. Primack

CHAPTER 84 **Postoperative Complications** 1269
Thomas O. Flukinger and Charles S. White

CHAPTER 85 **Chest Radiography in the Intensive Care Unit** 1288
Peder E. Horner and Steven L. Primack

PART SEVENTEEN: PLEURAL DISEASE

CHAPTER 86 **Pneumothorax** 1311
Jean M. Seely

CHAPTER **87** **Pleural Effusion** 1336

Jean M. Seely and Anoop P. Ayyappan

CHAPTER **88** **Benign Pleural Thickening** 1372

Jean M. Seely

CHAPTER **89** **Pleural Neoplasms** 1401

Jean M. Seely

PART EIGHTEEN: MEDIASTINUM

CHAPTER **90** **Pneumomediastinum** 1447

Tomás Franquet

CHAPTER **91** **Mediastinitis** 1457

Tomás Franquet

CHAPTER **92** **Anterior Mediastinal Masses** 1473

Kiminori Fujimoto and Nestor L. Müller

CHAPTER **93** **Middle and Posterior Mediastinal**

Masses 1526

Tomás Franquet

CHAPTER **94** **Paravertebral Masses** 1551

Kyung Soo Lee

PART NINETEEN: DIAPHRAGM AND CHEST WALL

CHAPTER **95** **Diaphragm** 1573

Nestor L. Müller and C. Isabela S. Silva

CHAPTER **96** **Chest Wall** 1590

Tomás Franquet and Jaume Llauger

Index I-1