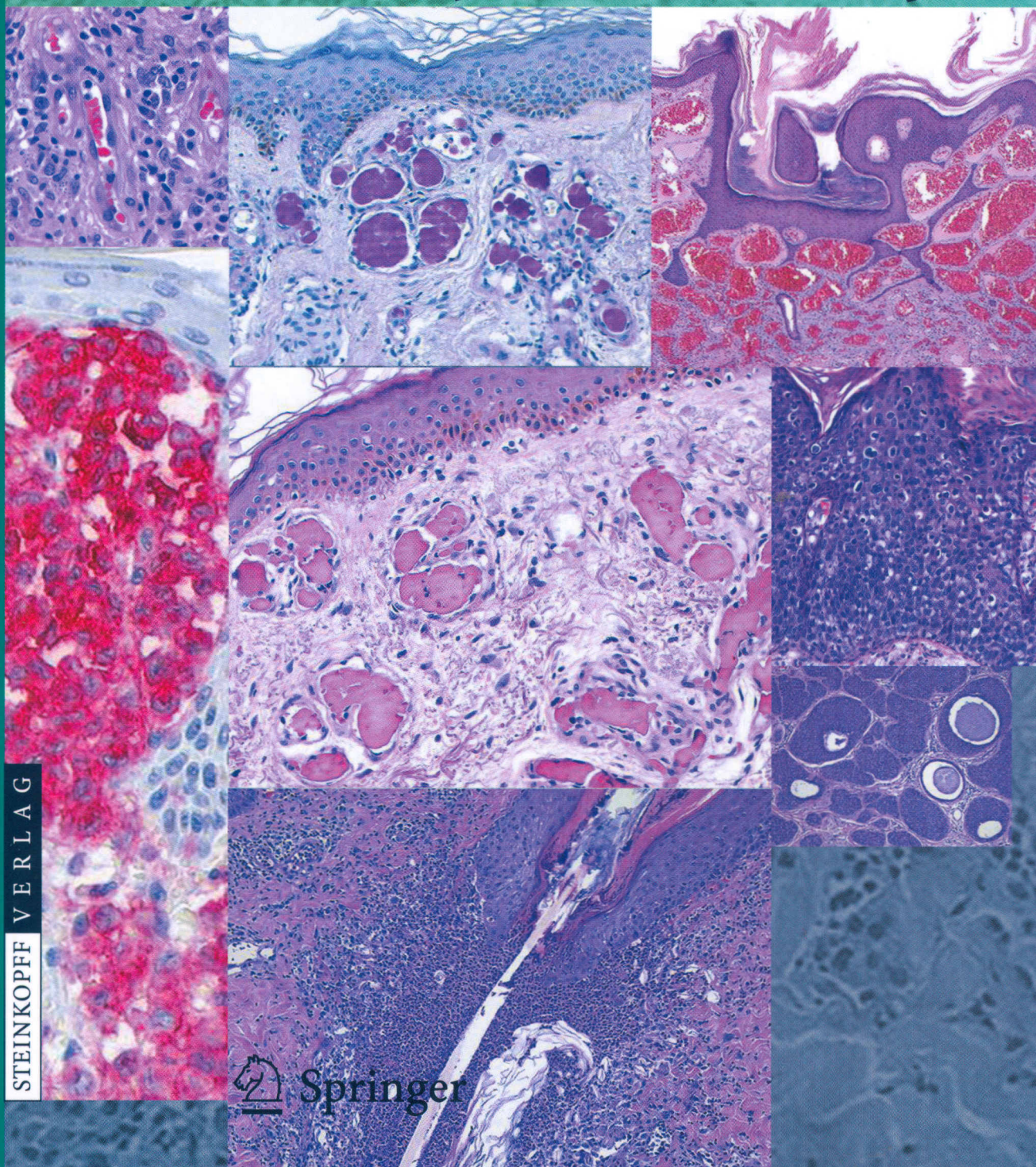


151547

W. KEMPF · M. HANTSCHKE
H. KUTZNER · W. BURGDORF

Dermatopathology



STEINKOPFF VERLAG



Springer

Contents

I Basic Principles

1.1	Principles of diagnosis	3
1.2	The skin biopsy	5
1.3	Histopathological techniques	7
1.3.1	Staining	7
1.3.2	Immunohistochemical stains	9
1.3.3	Immunofluorescence studies	11
1.3.4	Molecular biological procedures	12
1.4	Dermatopathologic glossary	15

II Inflammatory and Infectious Dermatoses

2.1	Epidermis – Spongiosis, acanthosis and hyperparakeratosis	19
2.1.1	Dermatitis	20
2.1.2	Prurigo	22
2.1.3	Psoriasis	24
2.1.4	Pustular psoriasis	26
2.1.5	Pityriasis rosea	28
2.1.6	Cutaneous fungal infections	30
2.1.7	Viral papillomas	32
2.1.8	Molluscum contagiosum	34
2.2	Epidermis – Acantholysis	37
2.2.1	Darier disease	38
2.2.2	Hailey-Hailey disease	40
2.2.3	Herpes virus infections	42
2.3	Bullous diseases	45
2.3.1	Pemphigus foliaceus	46
2.3.2	Pemphigus vulgaris	48
2.3.3	Bullous pemphigoid	50
2.3.4	Dermatitis herpetiformis	52
2.3.5	Porphyria cutanea tarda	54
2.4	Interface dermatoses	57
2.4.1	Erythema multiforme	58
2.4.2	Pityriasis lichenoides	60
2.4.3	Lichen planus	62
2.4.4	Lichen sclerosus	64
2.4.5	Lupus erythematosus	66
2.4.6	Pigmented purpuric dermatoses	68

2.5	Dermis – Vascular disorders	71
2.5.1	Leukocytoclastic vasculitis	72
2.5.2	Granuloma faciale and erythema elevatum et diutinum	74
2.5.3	Polyarteritis nodosa	76
2.5.4	Cryoglobulinemia	78
2.6	Dermis – Granulomatous inflammation	81
2.6.1	Granuloma annulare	82
2.6.2	Necrobiosis lipoidica	84
2.6.3	Sarcoidosis	86
2.6.4	Foreign body granuloma	88
2.6.5	Mycobacterial infections	90
2.6.6	Syphilis	92
2.6.7	Leishmaniasis	94
2.7	Dermis – Interstitial inflammation	97
2.7.1	Borreliosis	98
2.7.2	Morphea	100
2.8	Dermis – Diffuse mixed inflammatory infiltrates	103
2.8.1	Urticaria	104
2.8.2	Acute febrile neutrophilic dermatosis	106
2.8.3	Eosinophilic cellulitis	108
2.8.4	Arthropod assault reaction	110
2.9	Dermis – Degenerative and metabolic disorders	113
2.9.1	Chondrodermatitis helices nodularis chronica	114
2.9.2	Pseudoxanthoma elasticum	116
2.9.3	Xanthoma	118
2.10	Dermis – Inflammation of adnexal structures	121
2.10.1	Folliculitis	122
2.10.2	Alopecia areata	124
2.10.3	Lupus erythematosus of scalp	126
2.10.4	Folliculitis decalvans	128
2.11	Subcutaneous fat – Panniculitis	131
2.11.1	Erythema nodosum	132
2.11.2	Lupus panniculitis	134
2.12	Drug reactions	136
2.13	Artifactual damage	140

III Cysts

3.1	Epithelial cysts	145
3.1.1	Epidermoid cyst	146
3.1.2	Trichilemmal cyst	148
3.1.3	Steatocystoma	150
3.2	Pseudocysts	153
3.2.1	Digital mucous cyst	154

IV Hamartomas and Neoplasms

4.1	Epidermal hamartomas and neoplasms	159
4.1.1	Epidermal nevus	160
4.1.2	Nevus sebaceus	162
4.1.3	Seborrheic keratosis	164
4.1.4	Clear cell acanthoma	166
4.1.5	Porokeratosis	168
4.1.6	Actinic keratosis	170
4.1.7	Bowen disease	172
4.1.8	Squamous cell carcinoma	174
4.1.9	Keratoacanthoma	176
4.2	Melanocytic lesions	179
4.2.1	Mucosal melanotic macule	180
4.2.2	Lentigo simplex	182
4.2.3	Melanocytic nevi – junctional and compound types	184
4.2.4	Melanocytic nevi – dermal and congenital types	186
4.2.5	Halo nevus	188
4.2.6	Blue nevus	190
4.2.7	Dysplastic melanocytic nevus	192
4.2.8	Spitz nevus	194
4.2.9	Lentigo maligna and lentigo maligna melanoma	196
4.2.10	Superficial spreading melanoma	198
4.2.11	Nodular melanoma	200
4.2.12	Acrolentiginous melanoma	202
4.2.13	Desmoplastic melanoma	204
4.3	Adnexal tumors	207
4.3.1	Sebaceous hyperplasia	208
4.3.2	Pilomatricoma	210
4.3.3	Syringoma	212
4.3.4	Syringocystadenoma papilliferum	214
4.3.5	Poroma	216
4.3.6	Hidradenoma	218
4.3.7	Spiradenoma	220
4.3.8	Cylindroma	222
4.3.9	Paget disease	224
4.3.10	Trichoblastoma	226
4.3.11	Desmoplastic trichoepithelioma	228
4.3.12	Basal cell carcinoma	230
4.3.13	Fibroepithelioma of Pinkus	232
4.4	Soft tissue proliferations and neoplasms	235
4.4.1	Scar	236
4.4.2	Hypertrophic scar and keloid	238
4.4.3	Skin tag	240
4.4.4	Dermatofibroma	242
4.4.5	Dermatofibrosarcoma protuberans	244
4.4.6	Atypical fibroxanthoma	246
4.4.7	Leiomyoma	248
4.4.8	Nevus lipomatosus superficialis	250
4.4.9	Lipoma	252
4.4.10	Neurofibroma	254
4.4.11	Schwannoma	256
4.4.12	Merkel cell carcinoma	258

4.5	Vascular tumors	261
4.5.1	Hemangioma	262
4.5.2	Pyogenic granuloma	264
4.5.3	Angiokeratoma	266
4.5.4	Kaposi sarcoma	268
4.5.5	Angiosarcoma	270
4.6	Lymphomas and pseudolymphomas	273
4.6.1	Mycosis fungoides	274
4.6.2	Primary cutaneous CD30-positive lymphoproliferative diseases	276
4.6.3	Primary cutaneous follicle center B-cell lymphoma	278
4.6.4	Cutaneous B-cell pseudolymphoma	280
4.7	Histiocytoses and mastocytoses	283
4.7.1	Langerhans cell histiocytoses	284
4.7.2	Juvenile xanthogranuloma	286
4.7.3	Cutaneous mastocytoses	288
4.8.	Cutaneous metastases	290
	Subject Index	293