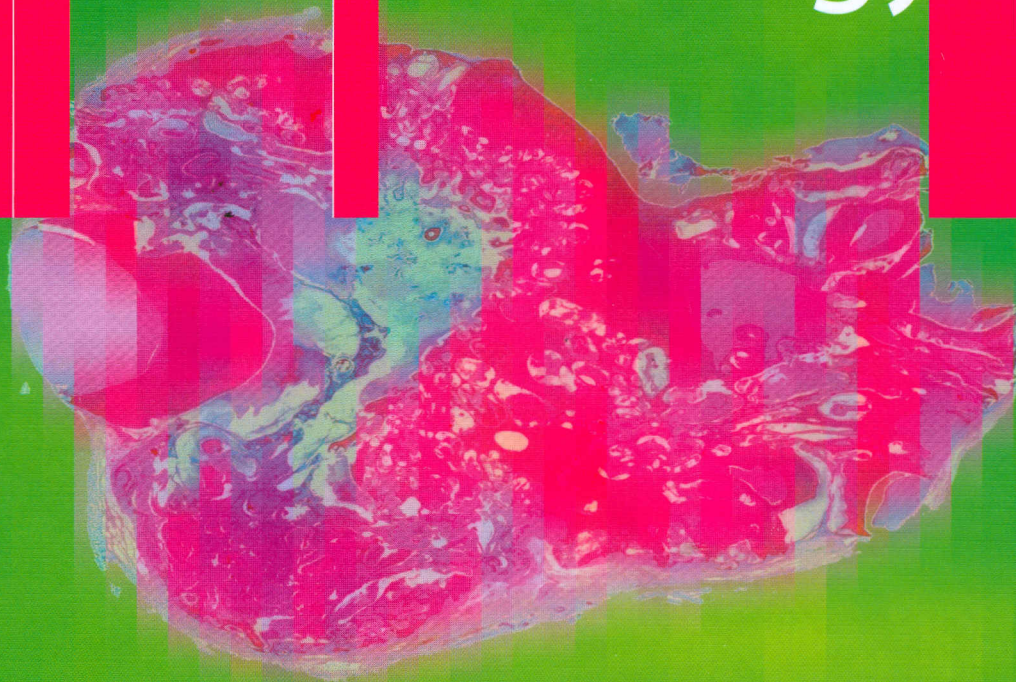


151587

Pieter J. Sootweg

Dental Pathology



A Practical Introduction

 Springer

Contents

1	Tooth Formation	1	4	Developmental Disturbances in Tissue Structure	19
2	Histology of the Teeth and Surrounding Structures	5	4.1	Enamel	19
2.1	Introduction	5	4.1.1	Amelogenesis Imperfecta ...	19
2.2	Dentin	5	4.1.2	Enamel Hypoplasia	21
2.3	Enamel	7	4.1.3	Enamel Opacities	21
2.4	Cementum	8	4.1.4	Dental Fluorosis	22
2.5	Dental Pulp	8	4.2	Dentin	22
2.6	Gingival Attachment	9	4.3	Developmental Structural Abnormalities Involving Both Enamel and Dentin	23
2.7	Periodontal Ligament	10	4.3.1	Odontodysplasia	23
3	Disturbed Tooth Form	11	4.3.2	Odontogenesis Imperfecta ..	23
3.1	Disturbances Arising During Tooth Formation	11	4.3.3	Rickets	24
3.1.1	Fusion	11	4.3.4	Segmental Odontomaxillary Dysplasia	24
3.1.2	Gemination and Twinning ..	11	5	Alterations Acquired After Tooth Eruption	27
3.1.3	Concrescence	11	5.1	Caries	27
3.1.4	Dens Invaginatus	11	5.2	Attrition	28
3.1.5	Dens Evaginatus	14	5.3	Abrasion	28
3.1.6	Dilaceration	15	5.4	Erosion	29
3.1.7	Taurodontism	15	5.5	Hypercementosis	29
3.1.8	Enamel Pearls	16	5.6	Cementicles	29
3.2	Posteruptively Acquired Disturbed Tooth Form	17	5.7	Secondary and Tertiary Dentin Formation	29

5.8	External Resorption	31
5.9	Tooth Fracture	32
5.10	Pigmentations	33
5.10.1	Tetracyclin Discoloration ...	33
6	Disturbed Tooth Eruption	35
6.1	Ankylosis	35
6.2	Premature Eruption	35
6.3	Local Conditions Causing Disturbed Eruption	37
7	Disorders of the Dental Pulp ..	39
7.1	Pulp Stones, False and True (Denticles)	39
7.2	Internal Resorption	39
7.3	Pulpitis	40
7.3.1	Periapical Disease	42
7.4	Pulp Polyp	42
8	Disorders of the Periodontal Tissues	45
8.1	Gingival Inflammation	45
8.2	Gingival Hyperplasia	46
8.3	Periodontitis	47
8.4	Osseous Dysplasia	47
9	Odontogenic Cysts	49
9.1	Odontogenic Cysts— Inflammatory	49
9.1.1	Radicular Cyst	49

9.1.2	Residual Cyst	51
9.1.3	Paradental Cyst	51
9.2	Odontogenic Cysts— Developmental	52
9.2.1	Dentigerous Cyst	52
9.2.2	Lateral Periodontal Cyst	54
9.2.3	Botryoid Odontogenic Cyst	55
9.2.4	Glandular Odontogenic Cyst	55
9.2.5	Primordial Cyst	56
9.2.6	Gingival Cyst	56
10	Odontogenic Tumours	59
10.1	Epithelial	59
10.1.1	Ameloblastoma	59
10.1.2	Calcifying Epithelial Odontogenic Tumour	61
10.1.3	Adenomatoid Odontogenic Tumour	61
10.1.4	Squamous Odontogenic Tumour	62
10.1.5	Keratocystic Odontogenic Tumour	63
10.2	Mesenchymal	63
10.2.1	Odontogenic Myxoma	64
10.2.2	Odontogenic Fibroma	65
10.2.3	Cementoblastoma	65
10.3	Odontogenic Tumours— Mixed Epithelial and Mesenchymal	66
10.3.1	Ameloblastic Fibroma	66
10.3.2	Ameloblastic Fibro-Odontoma	67
10.3.3	Odontoma—Complex Type	67
10.3.4	Odontoma—Compound Type	69
10.3.5	Odonto-Ameloblastoma ...	69
10.3.6	Calcifying Odontogenic Cyst	69
10.4	Odontogenic Tumours— Malignant	70
10.4.1	Malignant Ameloblastoma ..	70
10.4.2	Ameloblastic Carcinoma ...	71

10.4.3	Primary Intraosseous Carcinoma	71
10.4.4	Clear Cell Odontogenic Carcinoma	71
10.4.5	Ghost Cell Odontogenic Carcinoma	71
10.4.6	Odontogenic Sarcoma	71

11	Immature Odontogenic Tissues. A Source of Diagnostic Confusion	75
11.1	Introduction	75
11.2	Dental Papilla	75
11.3	Dental Follicle	77
	Subject Index	81