

151402

Direct Diagnosis in Radiology

# Cardiac Imaging

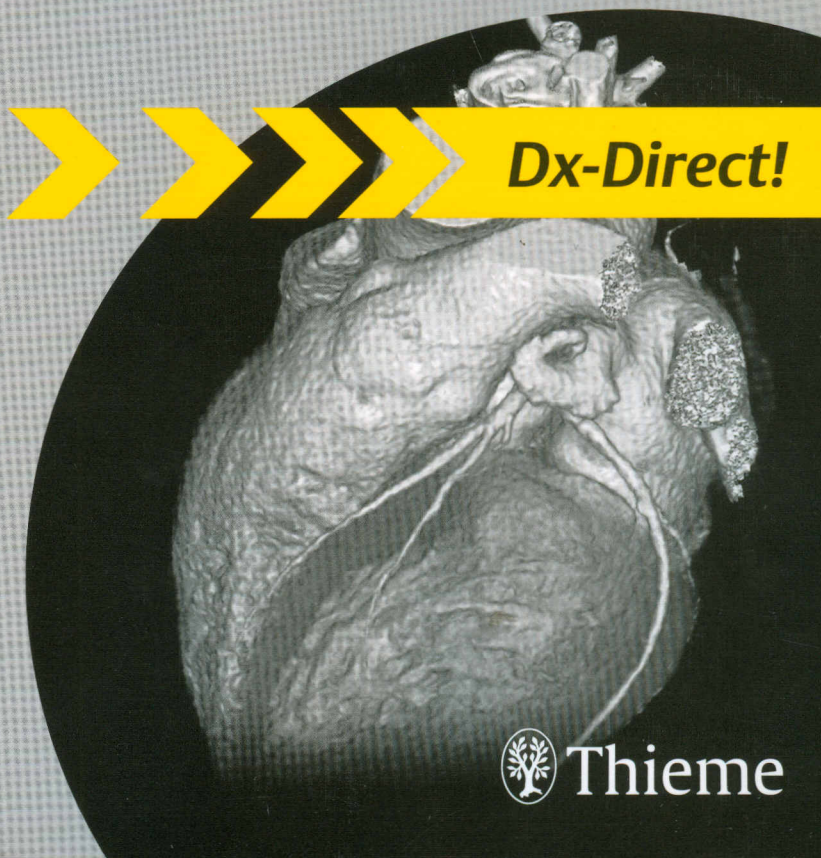
C. D. Claussen

S. Miller

M. Fenchel

U. Kramer

R. Riessen



**Dx-Direct!**



Thieme

## 1 Ischemic Heart Disease

*S. Miller, U. Kramer*

Coronary Heart Disease (CHD) ....	1	Prinzmetal Angina .....	21
Unstable Angina Pectoris .....	7	Aortocoronary Bypass Surgery ....	23
Acute Myocardial Infarction (AMI) ..	10	Coronary Anomalies .....	26
Chronic Myocardial Infarction ....	13	Bland–White–Garland Syndrome ..	28
Ventricular Aneurysm .....	16	Kawasaki Syndrome .....	31
Syndrome X .....	19		

## 2 Heart Failure

*R. Riessen*

Acute Heart Failure .....	34	Heart Transplantation .....	40
Chronic Heart Failure .....	37		

## 3 Acquired Valvular Heart Diseases

*U. Kramer*

Aortic Stenosis .....	43	Tricuspid Insufficiency .....	64
Aortic Insufficiency .....	46	Combined Valvular Disease .....	67
Mitral Stenosis .....	49	Mitral Valve Prolapse (MVP) .....	70
Mitral Insufficiency .....	52	Prosthetic Heart Valves .....	73
Pulmonary Stenosis .....	55	Ross Aortic Valve Replacement ...	76
Pulmonary Insufficiency .....	58	Aortic Valve Reconstruction (AVR) ..	79
Tricuspid Stenosis .....	61		

## 4 Cardiomyopathy

*S. Miller*

Dilated Cardiomyopathy (DCM) ...	82	Apical Ballooning .....	96
Hypertrophic Cardiomyopathy (HCM) .....	85	Sarcoidosis .....	99
Arrhythmogenic Right Ventricular Cardiomyopathy .....	88	Amyloidosis .....	102
Restrictive Cardiomyopathy (RCM) .....	91	Hemochromatosis, Hemosiderosis .....	105
Unclassified Cardiomyopathies (ILNC) .....	94	Uremic Cardiomyopathy .....	108
		Toxic Cardiomyopathy .....	111

**5 Inflammatory Heart Diseases***S. Miller*

Myocarditis .....	114	Hypereosinophilic Syndrome (Loeffler Endocarditis) .....	126
Acute Pericarditis .....	117	Postinfarction Pericarditis, Dressler Syndrome .....	129
Constrictive Pericarditis .....	120		
Infectious Endocarditis .....	123		

**6 Hypertension***R. Riessen*

Arterial Hypertension .....	131	Acute Pulmonary Hypertension, Pulmonary Embolism .....	137
Chronic Pulmonary Hypertension	134		

**7 Tumors and Other Masses***M. Fenchel*

Thrombus .....	141	Angiosarcoma .....	161
Myxoma .....	144	Undifferentiated Sarcoma .....	164
Lipoma .....	147	Rhabdomyosarcoma .....	167
Fibroma .....	150	Lymphoma .....	169
Papillary Fibroelastoma .....	153	Pulmonary Artery Sarcoma .....	172
Pericardial Cyst .....	155	Mediastinal Tumors .....	174
Metastases .....	158		

**8 Trauma***U. Kramer*

Cardiac Contusion .....	177	Coronary Dissection .....	183
Aortic Rupture .....	180	Pulmonary Artery Rupture .....	185

**9 Congenital Heart Diseases***M. Fenchel*

Atrial Septal Defect (ASD) .....	188	Tricuspid Atresia .....	209
Ventricular Septal Defect (VSD) .	191	Truncus Arteriosus .....	212
Eisenmenger Syndrome .....	194	Cor Triatriatum .....	214
Patent Ductus Arteriosus (PDA) .	196	Scimitar Syndrome .....	216
Bicuspid Aortic Valve .....	198	Atrioventricular Septal Defect (AVSD) .....	219
Coarctation of the Aorta .....	201	Ebstein Anomaly .....	222
Aortic Arch Anomalies .....	204	Tetralogy and Pentalogy of Fallot	225
Heterotaxy Syndrome .....	207		

Hypoplastic Left Heart Syndrome (HLHS, Single Ventricle) .....	229	Double-Outlet Right Ventricle (DORV) .....	241
Pulmonary Atresia .....	232	Total Anomalous Pulmonary Venous Connection (TAPVC) .....	244
Transposition of the Great Arteries (dextro-TGA) .....	235	Fontan Procedure .....	247
Corrected Transposition of the Great Arteries (levo-TGA) ....	238	Blalock–Taussig Shunt .....	253

## 10 Diseases of the Great Vessels

*U. Kramer*

Aortic Aneurysm .....	255	Thoracic Outlet Syndrome (TOS) .	269
Aortic Ectasia .....	257	Takayasu Arteritis .....	272
Aortic Dissection .....	259	Two-Chamber Long-Axis View Parallel to the Septum, LV .....	277
Carotid Stenosis .....	263		
Subclavian Steal Syndrome .....	266		

## 11 Standard Views of the Heart

*S. Miller*

Where are Structures Located in the Chest Radiograph? .....	275	Four-Chamber View .....	281
Standard Views of the Heart: Overview .....	276	LVOT .....	283
Two-Chamber Long-Axis View Parallel to the Septum, LV .....	277	LVOT, “Three-Chamber View” ....	284
Short-Axis View .....	279	Two-Chamber Long-Axis View Parallel to the Septum, RV .....	285
		RVOT .....	286

## 12 Appendix

*S. Miller*

Normal Values (Adults) .....	288	Classification of Pulmonary Venous Drainage Patterns .....	297
Classification of Myocardial Segments .....	290	NYHA Criteria for Symptoms of Heart Failure .....	298
Segmental Divisions of the Coronary Arteries .....	292	Classification of Thoraco- abdominal Aortic Aneurysms ....	301