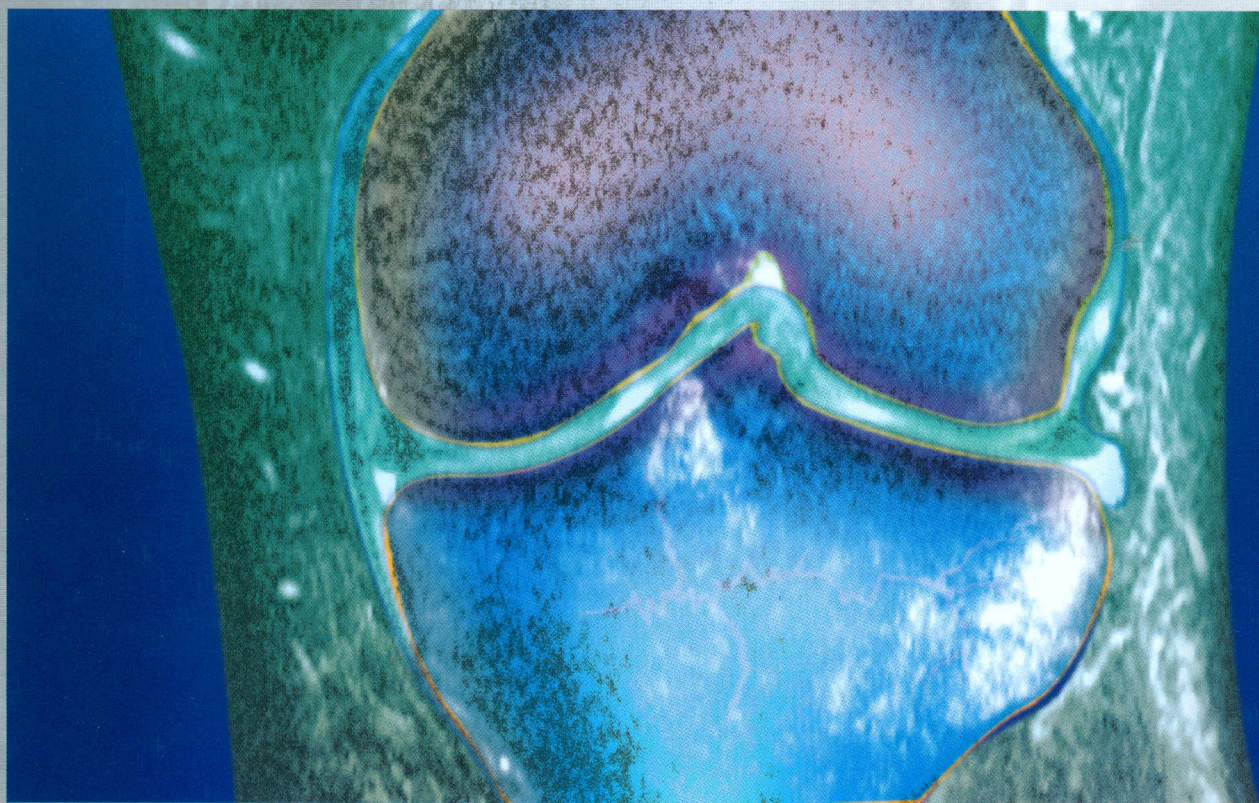


757373

# Imaging Strategies for the Knee

Juergen Maeurer





# Contents

## 1 Functional Anatomy of the Knee Joint

*M. L. Pretterklieber, F. Kainberger, and N. Leneva*

<b>Joint Mechanics</b> .....	1	<b>Soft Tissue Structures</b> .....	7
Flexion, Extension, Rotation .....	1	Menisci .....	7
The “Screw-home Mechanism” .....	1	Medial Meniscus .....	7
<b>Bony Structures</b> .....	2	Lateral Meniscus .....	7
Femur .....	2	Capsule–Ligament Complex .....	10
Tibia .....	3	Fibrous Capsule .....	10
Patella .....	4	Synovial Membrane and Synovial Fat Pads .....	11
Fabella .....	6	Tibial Collateral Ligament .....	11
Fibula .....	6	Fibular Collateral Ligament .....	13
		Anterior and Posterior Cruciate Ligaments .....	14
		Muscles of the Knee Joint .....	14
		Bursae of the Knee .....	14

## 2 Traumatic Disorders

*R.-J. Schroeder, M. Lorenz, J. Jerosch, and J. Maeurer*

<b>Fractures</b> .....	15	Inactivity Osteoporosis .....	44
Fracture Causes .....	16	Posttraumatic Arthritis .....	44
Traumatic Fractures .....	16	Plica Syndrome .....	46
Pathologic Fracture .....	26	Hoffa Disease .....	47
Fatigue Fracture, Stress Fracture .....	27	<b>Soft Tissue Injuries</b>	
Chondral and Osteochondral Fractures .....	29	<b>(Tendon, Muscle, Capsule, Ligament Apparatus)</b>	48
Occult Fracture, Bone Bruise .....	30	Ligament Rupture .....	48
Osteochondritis Dissecans .....	31	Tendon Rupture .....	52
<b>Fracture Complications</b> .....	37	Meniscal Lesions .....	54
Infection .....	37	<b>Dislocations</b> .....	60
Delayed Union and Pseudarthrosis .....	39	Patellar Dislocation .....	60
Osteonecrosis .....	40	Dislocation of the Knee .....	63
Heterotopic Ossification .....	43		

## 3 Degenerative Diseases

*R.-J. Schroeder, M. Lorenz, J. Jerosch, and J. Maeurer*

<b>Primary Osteoarthritis</b> .....	65	<b>Secondary Osteoarthritis</b> .....	72
Degeneration of the Knee Joint (Gonarthrosis) .....	65	<b>Fibrosis of the Infrapatellar Fat Pad</b> .....	75
Retropatellar Arthritis .....	68	<b>Meniscus Degeneration</b> .....	76

## 4 Inflammatory Diseases

*G. M. Lingg, C. Schorn, W. Flaig, and H. Thabe*

<b>Infectious Diseases of the Joint</b> .....	81	Sclerosing Osteomyelitis of Garré .....	90
Septic Arthritis .....	81	Chronic Recurrent Multifocal Osteomyelitis (CRMO) .....	91
<b>Osteomyelitis</b> .....	84	<b>Rheumatic Disorders: Chief Symptom Arthritis</b> .....	93
Acute Hematogenous Osteomyelitis .....	84	Rheumatoid Arthritis (RA) .....	94
Subacute Osteomyelitis, Brodie Abscess .....	86	Juvenile Idiopathic Arthritis (JIA) .....	98
Chronic and Chronic Recurrent Osteomyelitis .....	88		

<b>Rheumatic Disorders:</b>	
<b>Chief Symptoms Spondylitis and Arthritis (Seronegative Spondarthropathies)</b>	101
Ankylosing Spondylitis	101
Reiter Syndrome	103
Psoriatic Arthritis	104
<b>Rheumatic Syndromes Associated with Infections</b>	107
Lyme Disease	107

<b>Rheumatic Disorders of the Knee Joint—Surgical Therapy</b>	108
Synovectomy	108
Baker Cyst Resection	108
Arthrodesis	108
Endoprosthesis Reconstruction	108
<b>Connective Tissue Diseases</b>	109
Systemic Lupus Erythematosus	109
Progressive Systemic Sclerosis	111
Polymyositis, Dermatomyositis	112

## 5 Tumors and Tumorlike Lesions of the Knee Joint

*M. Breitenseher and M. Dominkus*

<b>Malignant Bone Tumors</b>	117
Osteosarcoma	117
Chondrosarcoma	122
Ewing Sarcoma	124
<b>Potentially Malignant Bone Tumors</b>	125
Giant Cell Tumor (GCT)	125
<b>Benign Primary Tumors of the Bone</b>	126
Osteoid Osteoma, Osteoblastoma	126
Enchondroma	128
Chondroblastoma	129

<b>Tumorlike Lesions of the Bone</b>	131
Osteochondroma	131
Juvenile Bone Cysts	132
Aneurysmal Bone Cyst (ABC)	132
Fibrous Dysplasia	135
Fibrous Cortical Defect	137
<b>Other Malignant Bone Tumors</b>	138
Plasmacytoma	138
Primary Lymphoma of Bone	139
Metastatic Bone Disease	140

## 6 Endocrine/Metabolic Disorders and Crystal-induced Diseases

*A. Scheurecker and J. Kramer*

<b>Osteomalacia and Rickets</b>	143
<b>Osteoporosis</b>	143
Generalized Osteoporosis	143
Regional Osteoporosis	144
Inactivity-induced Osteoporosis	144
Regional Migratory (Transient) Osteoporosis	145
Aggressive Regional Osteoporosis	145
Sudeck Atrophy (Reflex Sympathetic Dystrophy Syndrome)	146

<b>Hyperparathyroidism</b>	147
<b>Renal Osteodystrophy and Aluminum-induced Osteomalacia</b>	148
Renal Osteodystrophy	148
Aluminum-induced Osteomalacia	148
<b>Acromegaly</b>	149
<b>Calcium Pyrophosphate Crystal Deposition Disease</b>	150
<b>Gout (Arthritis Urica)</b>	152

## 7 Ischemic Diseases

*J. Kramer and A. Scheurecker*

<b>Osteonecrosis</b>	155
<b>Bone Infarction</b>	158

<b>Osteochondritis Dissecans</b>	159
----------------------------------	-----

## 8 Hematologic Diseases

*A. Scheurecker and J. Kramer*

<b>Anemia(s)</b>	163
Sickle-cell Anemia	163
Thalassemia	165
<b>Leukemia</b>	166

<b>Hemophilic Arthropathy</b>	167
<b>Plasmacytoma</b>	168
Generalized Plasmacytoma (Multiple Myeloma, Kahler Disease)	168

## 9 Neuropathic Osteoarthropathy

*J. Kramer and A. Scheurecker*

	169
--	-----

# 10 Pediatric Radiology

M. Reither

## Normal Skeletal Development

### and Normal Variants . . . . . 171

Epiphyseal Ossification of the Distal Femur . . . 171

Ossification of the Proximal Tibia . . . . . 172

Ossification of the Proximal Fibula . . . . . 172

Ossification of the Patella . . . . . 173

Other Variants . . . . . 174

### Skeletal Malformations . . . . . 175

Blount Disease . . . . . 175

Multiple Epiphyseal Dysplasia . . . . . 175

Multiple Cartilaginous Exostoses . . . . . 176

Dysplasia of the Femoropatellar Joint . . . . . 177

Other Malformation Syndromes . . . . . 179

### Trauma . . . . . 180

Fractures . . . . . 180

Supracondylar Fracture of the Distal Femur . . . 180

Fracture of the Distal Femoral Epiphysis . . . . . 181

Epiphyseal Fracture of the Proximal Tibia

(Not Crossing the Physis) . . . . . 182

Epiphyseal Fracture of the Proximal Tibia

Through the Physis . . . . . 183

Tibial Metaphyseal Fracture . . . . . 183

Stress Fracture . . . . . 184

Soft Tissue Trauma . . . . . 184

Patellar Dislocation . . . . . 185

Patellar Fractures . . . . . 185

Internal Derangement of the Knee . . . . . 185

Isolated Femoral Bony Avulsion of the

Collateral Ligament . . . . . 186

Nonosseous Ligament and Meniscal Lesions . . 187

Osteonecrosis Dissecans . . . . . 188

Osgood–Schlatter Disease . . . . . 189

Sinding–Larson–Johansson Disease . . . . . 190

### Tumors . . . . . 191

Benign Tumors . . . . . 191

Baker Cyst . . . . . 191

Osteochondroma . . . . . 192

Nonossifying Fibroma (Fibrous Cortical Defect) 193

Osteoid Osteoma, Osteoblastoma . . . . . 193

Malignant Tumors . . . . . 194

Osteosarcoma . . . . . 194

### Inflammatory Diseases . . . . . 195

Acute Osteomyelitis . . . . . 195

Juvenile Rheumatoid Arthritis (JRA) . . . . . 196

Lyme Arthritis . . . . . 197

### Metabolic Diseases . . . . . 198

Vitamin D-Deficiency Rickets . . . . . 198

Renal Osteodystrophy . . . . . 199

### Hematology . . . . . 200

Sickle-cell Anemia and  $\beta$ -Thalassemia . . . . . 200

Leukemia . . . . . 201

Hemophilia A . . . . . 202

**Further Reading** . . . . . 203

**Index** . . . . . 204