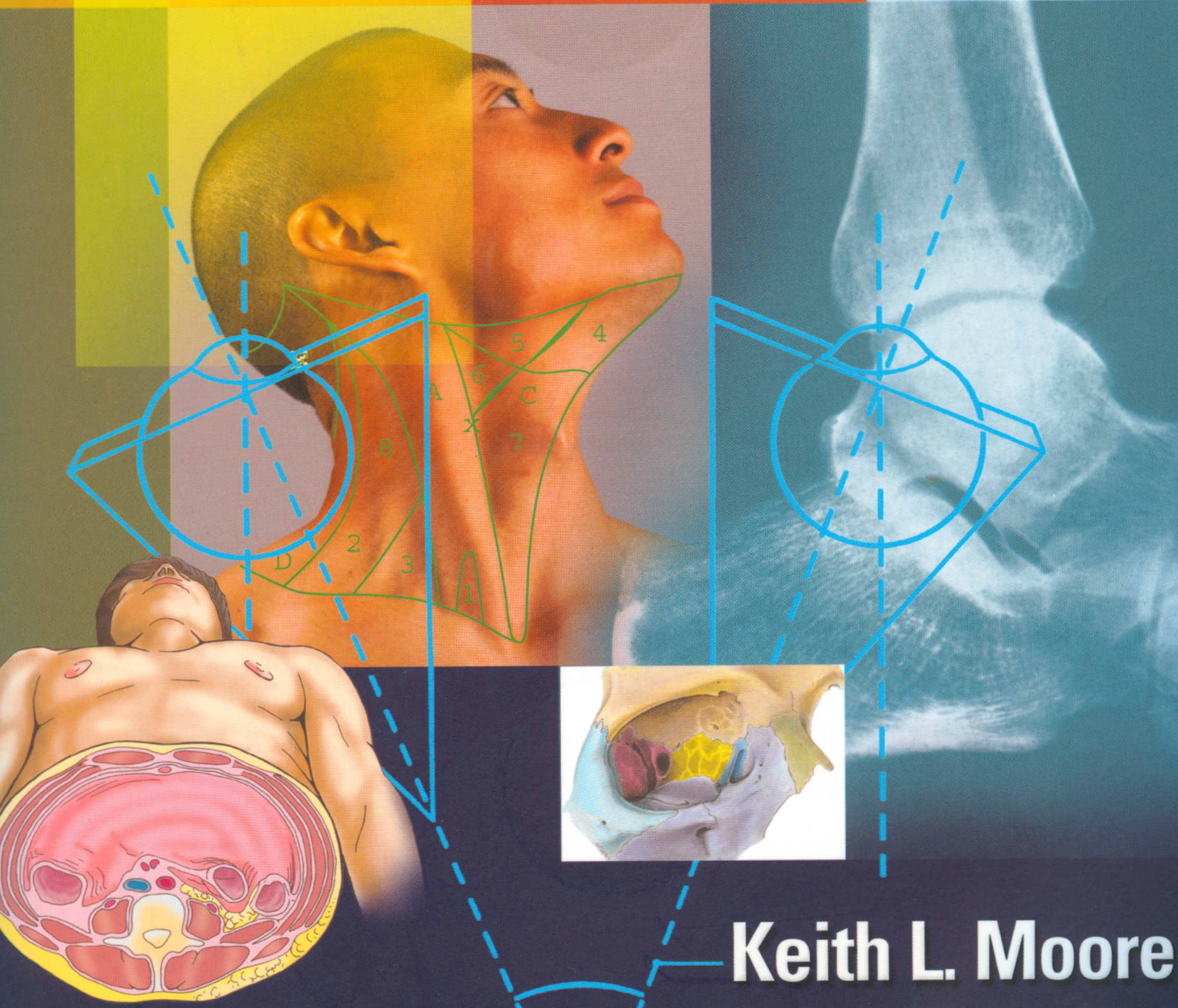


151353

Includes
2 FREE CD-ROMs
full of student
resources!

Clinically Oriented ANATOMY

FIFTH EDITION



Keith L. Moore
Arthur F. Dalley



LIPPINCOTT WILLIAMS & WILKINS

Introduction to Clinically Oriented Anatomy

- A Brief History of Anatomy / **2**
- Approaches to Studying Anatomy / **2**
 - Regional Anatomy / **2**
 - Systemic Anatomy / **3**
 - Clinical Anatomy / **4**
- Anatomicomedical Terminology / **4**
 - Anatomical Position / **5**
 - Anatomical Planes / **5**
 - Terms of Relationship and Comparison / **6**
 - Terms of Laterality / **7**
 - Terms of Movement / **7**
 - Structure of Terms / **11**
 - Abbreviations of Terms / **12**
- Anatomical Variations / **12**
- Integumentary System / **12**
- Fascias, Fascial Compartments, Bursae, and Potential Spaces / **16**
- Skeletal System / **18**
 - Cartilage and Bones / **19**
 - Joints / **26**
- Muscle Tissue and the Muscular System / **30**
 - Types of Muscle (Muscle Tissue) / **30**
 - Skeletal Muscles / **30**
 - Cardiac Striated Muscle / **38**
 - Smooth Muscle / **38**
- Cardiovascular System / **39**
 - Arteries / **39**
 - Veins / **42**
 - Blood Capillaries / **44**
- Lymphatic System / **44**
- Nervous System / **47**
 - Central Nervous System / **47**
 - Peripheral Nervous System / **48**
 - Somatic Nervous System / **58**
 - Autonomic Nervous System / **58**
- ◊ Medical Imaging Techniques / **67**
 - Conventional Radiography / **67**
 - Computerized Tomography / **68**
 - Ultrasonography / **69**
 - Magnetic Resonance Imaging / **70**
 - Nuclear Medicine Imaging / **72**

1

Thorax

- Thoracic Wall / **77**
 - Skeleton of the Thoracic Wall / **77**
 - Thoracic Apertures / **84**
 - Joints of the Thoracic Wall / **86**
 - Movements of the Thoracic Wall / **90**
- ◊ Surface Anatomy of the Thoracic Wall Skeleton / **91**
 - Muscles of the Thoracic Wall / **93**
 - Fascia of the Thoracic Wall / **98**
 - Nerves of the Thoracic Wall / **99**
 - Vasculature of the Thoracic Wall / **102**
 - Breasts / **105**
- ◊ Surface Anatomy of the Thoracic Wall Musculature and Breasts / **111**
- Viscera of the Thoracic Cavity / **112**
 - Pleurae and Lungs / **114**
- ◊ Surface Anatomy of the Pleurae and Lungs / **133**
 - Mediastinum / **135**
 - Pericardium / **137**
 - The Heart and Great Vessels / **141**
- ◊ Surface Anatomy of the Heart and Great Vessels / **167**
 - Superior Mediastinum / **169**
 - Posterior Mediastinum / **177**
 - Anterior Mediastinum / **184**
- ◊ Medical Imaging of the Thorax / **185**
 - Radiography / **185**
 - Echocardiography / **191**
 - CT and MRI / **191**

2

Abdomen

- Overview: Walls, Cavities, Regions, and Planes / **194**
- Anterolateral Abdominal Wall / **196**
 - Fascia of the Anterolateral Abdominal Wall / **196**
 - Muscles of the Anterolateral Abdominal Wall / **198**
 - Nerves of the Anterolateral Abdominal Wall / **206**
 - Vessels of the Anterolateral Abdominal Wall / **210**
- Internal Surface of the Anterolateral Abdominal Wall / **213**

- Inguinal Region / **214**
- ◊ **Surface Anatomy of the Anterolateral Abdominal Wall / 230**
- Peritoneum and Peritoneal Cavity / **231**
 - Embryology of the Peritoneal Cavity / **234**
 - Peritoneal Formations / **235**
 - Subdivisions of the Peritoneal Cavity / **238**
- Abdominal Viscera / **241**
 - Esophagus / **244**
 - Stomach / **248**
- ◊ **Surface Anatomy of the Stomach / 258**
 - Small Intestine / **259**
 - Large Intestine / **271**
 - Spleen / **281**
 - Pancreas / **286**
- ◊ **Surface Anatomy of the Spleen and Pancreas / 288**
 - Liver / **289**
- ◊ **Surface Anatomy of the Liver / 300**
 - Biliary Ducts and Gallbladder / **301**
 - Kidneys, Ureters, and Suprarenal Glands / **308**
- ◊ **Surface Anatomy of the Kidneys and Ureters / 317**
 - Summary of the Innervation of the Abdominal Viscera / **321**
- Diaphragm / **325**
 - Vessels and Nerves of the Diaphragm / **326**
 - Diaphragmatic Apertures / **328**
 - Actions of the Diaphragm / **329**
- Posterior Abdominal Wall / **331**
 - Fascia of the Posterior Abdominal Wall / **331**
 - Muscles of the Posterior Abdominal Wall / **333**
 - Nerves of the Posterior Abdominal Wall / **335**
 - Vessels of the Posterior Abdominal Wall / **337**
- ◊ **Surface Anatomy of the Abdominal Aorta / 340**
- ◊ **Medical Imaging of the Abdomen / 343**

3 Pelvis and Perineum

- Introduction to the Pelvis and Perineum / **357**
- Pelvic Girdle / **357**
 - Bones and Features of the Pelvic Girdle / **358**
 - Orientation of the Pelvic Girdle / **360**
 - Joints and Ligaments of the Pelvic Girdle / **364**
- Pelvic Cavity / **368**
- Walls and Floor of the Pelvic Cavity / **369**
 - Peritoneum and Peritoneal Cavity of the Pelvis / **376**
 - Pelvic Fascia / **377**
- Neurovascular Structures of the Pelvis / **379**
 - Pelvic Nerves / **379**
 - Pelvic Arteries / **383**
 - Pelvic Veins / **389**
 - Lymph Nodes of the Pelvis / **391**

- Pelvic Viscera / **391**
 - Urinary Organs / **391**
 - Male Internal Genital Organs / **405**
 - Female Internal Genital Organs / **410**
 - Rectum / **429**
- Perineum / **433**
 - Fascia and Pouches of the Urogenital Triangle / **438**
 - Features of the Anal Triangle / **442**
 - Male Perineum / **451**
 - Female Perineum / **461**
- ◊ **Medical Imaging of the Pelvis and Perineum / 467**
 - Radiography / **467**
 - Ultrasonography / **468**
 - Computed Tomography / **469**
 - Magnetic Resonance Imaging / **471**

4 Back

- Overview of Back and Vertebral Column / **478**
- Vertebrae / **478**
 - Structure and Function of the Vertebrae / **480**
 - Regional Characteristics of the Vertebrae / **48**
 - Ossification of the Vertebrae / **494**
 - Variations in the Vertebrae / **497**
- Vertebral Column / **497**
 - Joints of the Vertebral Column / **497**
 - Movements of the Vertebral Column / **511**
 - Curvatures of the Vertebral Column / **513**
 - Vasculature of the Vertebral Column / **516**
 - Nerves of the Vertebral Column / **518**
- Contents of the Vertebral Canal / **521**
 - Spinal Cord / **521**
 - Spinal Nerve Roots / **521**
 - Spinal Meninges and Cerebrospinal Fluid / **52**
 - Vasculature of the Spinal Cord and Spinal Nerve Roots / **529**
- ◊ **Surface Anatomy of the Vertebral Column / 531**
- Muscles of the Back / **534**
 - Extrinsic Back Muscles / **534**
 - Intrinsic Back Muscles / **534**
- ◊ **Surface Anatomy of the Back Muscles / 543**
 - Suboccipital and Deep Neck Muscles / **544**
- ◊ **Medical Imaging of the Back / 547**
 - Radiography / **547**
 - Myelography / **548**
 - Computed Tomography / **548**
 - Magnetic Resonance Imaging / **548**

5 Lower Limb

- Overview of the Lower Limb / **555**
- Development of the Lower Limb / **556**
- Bones of the Lower Limb / **556**

Arrangement of Lower Limb Bones / **558**

Hip Bone / **560**

Femur / **563**

Tibia and Fibula / **566**

Bones of the Foot / **570**

◊ **Surface Anatomy of the Lower Limb Bones / 573**

Fascia, Vessels, and Cutaneous Nerves of the Lower Limb / **578**

Subcutaneous Tissue and Fascia / **578**

Venous Drainage of the Lower Limb / **580**

Lymphatic Drainage of the Lower Limb / **584**

Cutaneous Innervation of the Lower Limb / **585**

Posture and Gait / **588**

Standing at Ease / **588**

Walking: The Gait Cycle / **589**

Thigh and Gluteal Region / **589**

Anterior Thigh Muscles / **591**

Medial Thigh Muscles / **597**

Neurovascular Structures and Relationships in the Anteromedial Thigh / **600**

Hip and Buttocks: The Gluteal Region / **607**

Gluteal Muscles / **608**

Posterior Thigh Muscles / **616**

Neurovascular Structures of the Gluteal Region and Posterior Thigh / **619**

◊ **Surface Anatomy of the Gluteal Region and Thigh / 626**

Popliteal Fossa / **632**

Fascia of the Popliteal Fossa / **634**

Neurovascular Structures and Relationships in the Popliteal Fossa / **634**

Leg / **636**

Anterior Compartment of the Leg / **638**

Lateral Compartment of the Leg / **644**

Posterior Compartment of the Leg / **647**

◊ **Surface Anatomy of the Leg / 656**

Foot / **658**

Skin and Fascia of the Foot / **660**

Muscles of the Foot / **663**

Neurovascular Structures and Relationships in the Foot / **668**

Joints of the Lower Limb / **672**

Hip Joint / **675**

Knee Joint / **684**

Tibiofibular Joints / **701**

Ankle Joint / **702**

Foot Joints / **707**

◊ **Surface Anatomy of the Ankle and Foot / 714**

◊ **Medical Imaging of the Lower Limb / 717**

Radiography / **717**

Arteriography / **720**

Computed Tomography / **720**

Magnetic Resonance Imaging / **720**

Upper Limb

Overview / **726**

Comparison of the Upper and Lower Limbs / **726**

Bones of the Upper Limb / **728**

Clavicle / **729**

Scapula / **730**

Humerus / **732**

Bones of the Forearm / **734**

Bones of the Hand / **737**

◊ **Surface Anatomy of the Upper Limb Bones / 739**

Superficial Structures of the Upper Limb / **742**

Fascia of the Upper Limb / **742**

Cutaneous Nerves of the Upper Limb / **745**

Superficial Veins of the Upper Limb / **748**

Lymphatic Drainage of the Upper Limb / **749**

Anterior Axioappendicular Muscles of the Upper Limb / **750**

Posterior Axioappendicular and Scapulohumeral Muscles / **753**

Superficial Posterior Axioappendicular (Extrinsic Shoulder) Muscles / **753**

Deep Posterior Axioappendicular (Extrinsic Shoulder) Muscles / **758**

Scapulohumeral (Intrinsic Shoulder) Muscles / **760**

Axilla / **763**

Axillary Artery / **766**

Axillary Vein / **770**

Axillary Lymph Nodes / **771**

Brachial Plexus / **773**

◊ **Surface Anatomy of the Pectoral and Scapular Regions / 781**

Arm / **784**

Muscles of the Arm / **784**

Brachial Artery / **791**

Veins of the Arm / **794**

Nerves of the Arm / **794**

Cubital Fossa / **795**

◊ **Surface Anatomy of the Arm and Cubital Fossa / 799**

Forearm / **801**

Compartments of the Forearm / **801**

Muscles of the Forearm / **803**

Arteries of the Forearm / **814**

Veins of the Forearm / **818**

Nerves of the Forearm / **819**

◊ **Surface Anatomy of the Forearm / 825**

Hand / **826**

Fascia of the Palm / **828**

Muscles of the Hand / **831**

Long Flexor Tendons and Tendon Sheaths in the Hand / **836**

Arteries of the Hand / **838**

Veins of the Hand / **838**

Nerves of the Hand / **838**

◊ **Surface Anatomy of the Hand / 845**

- Joints of the Upper Limb / **848**
 - Sternoclavicular Joint / **848**
 - Acromioclavicular Joint / **851**
 - Glenohumeral Joint / **853**
 - Elbow Joint / **860**
 - Proximal Radioulnar Joint / **863**
 - Distal Radioulnar Joint / **866**
 - Wrist Joint / **869**
 - Intercarpal Joints / **871**
 - Carpometacarpal and Intermetacarpal Joints / **873**
 - Metacarpophalangeal and Interphalangeal Joints / **873**
- ◊ **Medical Imaging of the Upper Limb / 874**
 - Radiography / **874**
 - Ultrasonography / **880**
 - Arteriography / **880**
 - Computed Tomography / **880**
 - Magnetic Resonance Imaging / **881**

7 Head

- Overview / **886**
- Cranium / **886**
 - Facial Aspect of the Cranium / **889**
 - Lateral Aspect of the Cranium / **892**
 - Occipital Aspect of the Cranium / **894**
 - Superior Aspect of the Cranium / **895**
 - External Surface of the Cranial Base / **895**
 - Internal Surface of the Cranial Base / **897**
 - Walls of the Cranial Cavity / **901**
- Structure of the Scalp / **906**
- Cranial Meninges / **908**
 - Dura Mater / **908**
 - Leptomeninges (Arachnoid Mater and Pia Mater) / **917**
 - Meningeal Spaces / **917**
- Brain / **921**
 - Parts of the Brain / **921**
 - Ventricular System of the Brain / **923**
 - Arterial Blood Supply of the Brain / **927**
 - Venous Drainage of the Brain / **932**
- Face / **933**
 - Muscles of the Face and Scalp / **933**
 - Nerves of the Face / **939**
 - Superficial Vasculature of the Face and Scalp / **947**
- Parotid Gland / **953**
- ◊ **Surface Anatomy of the Head / 956**
- Orbit, Orbital Region, and Eyeball / **957**
 - Eyelids and Lacrimal Apparatus / **961**
 - The Eyeball / **964**
 - Extraocular Muscles of the Orbit / **968**
 - Nerves of the Orbit / **972**
 - Vasculature of the Orbit / **973**
- ◊ **Surface Anatomy of the Eyeball and Lacrimal Apparatus / 976**

- Temporal Region / **976**
 - Temporal Fossa / **976**
 - Infratemporal Fossa / **978**
 - Temporomandibular Joint / **981**
 - Oral Region / **987**
 - Oral Cavity / **987**
 - Lips, Cheeks, and Gingivae / **990**
 - Teeth / **992**
 - Palate / **996**
 - Tongue / **1002**
 - Salivary Glands / **1008**
 - Pterygopalatine Fossa / **1010**
 - Pterygopalatine Part of the Maxillary Artery / **1010**
 - Maxillary Nerve / **1011**
 - Nose / **1013**
 - External Nose / **1013**
 - Nasal Cavity / **1015**
 - Vasculature and Innervation of the Nose / **1015**
 - Paranasal Sinuses / **1019**
 - Ear / **1022**
 - External Ear / **1022**
 - Middle Ear / **1026**
 - Internal Ear / **1033**
 - ◊ **Medical Imaging of the Head / 1037**
 - Radiography / **1037**
 - Computed Tomography / **1037**
 - Magnetic Resonance Imaging / **1037**
 - Ultrasonography / **1038**
- ## 8 Neck
- Overview / **1046**
 - Bones of the Neck / **1047**
 - Cervical Vertebrae / **1047**
 - Hyoid Bone / **1047**
 - Fascia of the Neck / **1049**
 - Cervical Subcutaneous Tissue and the Platysma / **1049**
 - Deep Cervical Fascia / **1049**
 - Superficial Structures of the Neck: The Cervical Regions / **1053**
 - Sternocleidomastoid Region / **1053**
 - Posterior Cervical Region / **1055**
 - Lateral Cervical Region / **1057**
 - Anterior Cervical Region / **1065**
 - ◊ **Surface Anatomy of the Cervical Regions and Triangles of the Neck / 1073**
 - Deep Structures of the Neck / **1076**
 - Prevertebral Muscles / **1076**
 - Root of the Neck / **1076**
 - Viscera of the Neck / **1083**
 - Endocrine Layer of the Cervical Viscera / **1083**
 - Respiratory Layer of the Cervical Viscera / **1083**
 - Alimentary Layer of the Cervical Viscera / **1111**

Lymphatics in the Neck / **1114**

⊕ **Surface Anatomy of the Endocrine and Respiratory Layers of the Cervical Viscera / 1115**

⊕ **Medical Imaging of the Neck / 1116**

Radiography / **1116**

Computed Tomography / **1117**

Magnetic Resonance Imaging / **1117**

Ultrasonography / **1121**

9 Summary of Cranial Nerves

Overview / **1124**

Olfactory Nerve (CN I) / **1129**

Optic Nerve (CN II) / **1132**

Oculomotor Nerve (CN III) / **1136**

Trochlear Nerve (CN IV) / **1137**

Trigeminal Nerve (CN V) / **1139**

Ophthalmic Nerve (CN V₁) / **1139**

Maxillary Nerve (CN V₂) / **1139**

Mandibular Nerve (CN V₃) / **1139**

Abducent Nerve (CN VI) / **1142**

Facial Nerve (CN VII) / **1143**

Branchial Motor / **1143**

Presynaptic Parasympathetic / **1143**

General Sensory / **1143**

Taste (Special Sensory) / **1143**

Vestibulocochlear Nerve (CN VIII) / **1146**

Glossopharyngeal Nerve (CN IX) / **1147**

Branchial Motor / **1148**

Parasympathetic (Visceral Motor) / **1148**

Sensory (General Sensory) / **1149**

Taste (Special Sensory) / **1149**

Vagus Nerve (CN X) / **1150**

Spinal Accessory Nerve (CN XI) / **1151**

Hypoglossal Nerve (CN XII) / **1153**