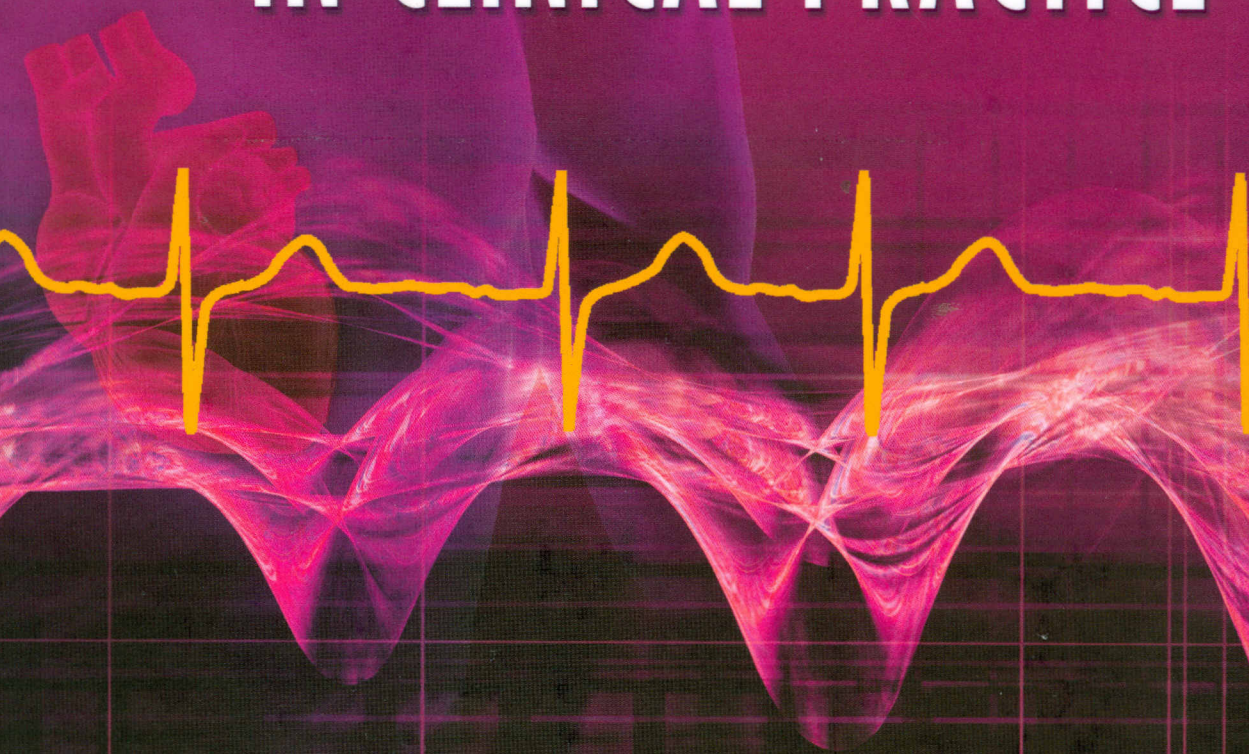


151358

Surawicz  
Knillans

**CHOU'S**  
**ELECTROCARDIOGRAPHY**  
**IN CLINICAL PRACTICE**



Sixth Edition

SAUNDERS  
ELSEVIER

## SECTION I ADULT ELECTROCARDIOGRAPHY 1

### 1 Normal Electrocardiogram: Origin and Description 1

Origin of the Electrocardiogram  
Methods of Recording  
Normal ECG  
Common Normal Variants

### 2 Atrial Abnormalities 29

Atrial Depolarization  
Right Atrial Abnormalities  
Left Atrial Abnormality  
Biatrial Enlargement: Diagnostic Criteria  
Atrial Enlargement in the Presence of Atrial Fibrillation  
Atrial Repolarization

### 3 Ventricular Enlargement 45

Left Ventricular Enlargement (Hypertrophy and Dilation)  
Right Ventricular Hypertrophy and Dilation  
Combined Ventricular Hypertrophy

### 4 Left Bundle Branch Block 75

Recognition of Myocardial Ischemia and Myocardial Infarction in the Presence of LBBB  
Functional Bundle Branch Block

### 5 Right Bundle Branch Block 95

Complete Right Bundle Branch Block  
Incomplete Right Bundle Branch Block

### 6 Other Intraventricular Conduction Disturbances 108

Fascicular Blocks  
Bilateral, Bifascicular, and Trifascicular Bundle Branch Block  
Intraventricular Conduction Disturbances Associated with Myocardial Infarction and Periinfarction Block  
Nonspecific Intraventricular Conduction Disturbances

### 7 Acute Ischemia: Electrocardiographic Patterns 124

Systolic and Diastolic Currents of Injury  
Depression and Elevation of the ST Segment

PQ Segment Elevation and Depression  
Localization of ST Segment Elevation and Reciprocal ST Segment Depression

### 8 Myocardial Infarction and Electrocardiographic Patterns Simulating Myocardial Infarction 162

Myocardial Infarction  
Evolution of ECG Patterns for Acute Q Wave MI  
Thrombolytic Treatment and Primary Angioplasty in Acute MI  
Sensitivity and Specificity of the ECG  
ECG Abnormalities Simulating MI

### 9 Non-Q Wave Myocardial Infarction, Non-ST Elevation Myocardial Infarction, Unstable Angina Pectoris, Myocardial Ischemia 205

Non-ST Elevation Myocardial Infarction (NSTEMI)  
Non-Q Wave Myocardial Infarction (NQMI)  
Unstable Angina Pectoris (UAP)  
Repolarization Abnormalities Simulating Myocardial Ischemia  
T Wave Abnormalities  
Silent Myocardial Ischemia  
Atrial Infarction

### 10 Stress Test 221

BORYS SURAWICZ and MORTON TAVEL

Introduction  
Indications and Contraindications  
Safety of the Exercise Test  
Graded Exercise Test  
Blood Pressure Response to Exercise  
Heart Rate Response to Exercise  
Cardiac Auscultation  
Recording Techniques  
Diagnostic Accuracy of the Exercise Test in CAD:  
Sensitivity and Specificity of the Conventional Criteria  
Predictive Value of a Test Result  
Criteria for a Positive Exercise Test  
Positive Exercise Tests in the Absence of Obstructive CAD  
Causes of False-Negative Responses  
Exercise Testing in Patients with Abnormal Resting ECGs  
Pharmacologic Stress Tests  
Prognostic Value of Exercise Testing  
Exercise Testing after MI  
Can the ECG Stress Test Rule Out Presence of Significant CAD?  
Exercise Testing and Arrhythmias

**11 Pericarditis and Cardiac Surgery 256**

Pericarditis  
ECG Changes after Cardiac Surgery

**12 Diseases of the Heart and Lungs 273**

Valvular Heart Disease  
Cardiomyopathies  
Connective Tissue Diseases  
Endocrine Disorders  
Metabolic Disturbances  
Miscellaneous Conditions  
Granulomatous and Infectious Cardiomyopathies  
Heart Transplantation  
Pulmonary Diseases  
Congenital Heart Disease in Adults

**13 Sinus Rhythms 327**

Initiation of the Sinus Impulse  
Sinus Rate  
Sinus Arrhythmias  
Sick Sinus Syndrome  
Detection of Sinus Node Dysfunction  
Heart Rate Variability  
Heart Rate Turbulence

**14 Atrial Rhythms 345**

Premature Atrial Impulses: Atrial Extrasystoles,  
Premature Atrial Depolarizations  
Ectopic Atrial Rhythm, Accelerated Atrial Rhythm  
Automatic Ectopic Atrial Tachycardia  
Intraatrial Reentry Tachycardia  
Paroxysmal Atrial Tachycardia with Block  
Atrial Standstill  
Multifocal Atrial or Chaotic Tachycardia  
Atrial Parasystole  
Atrial Dissociation

**15 Atrial Flutter and Atrial Fibrillation 361**

Atrial Flutter  
Atrial Fibrillation

**16 Atrioventricular Junctional Rhythms 384**

Coronary Sinus Rhythm  
Passive AV Junctional Impulses and Rhythms  
Active-Type AV Junctional Rhythm and Junctional  
Tachycardia  
AV Dissociation  
AV Nodal Reentry  
Reciprocal Impulses

**17 Ventricular Arrhythmias 405**

Premature Ventricular Complexes  
Aberrant Intraventricular Conduction

Heart Rate Turbulence  
Clinical Correlation  
Ventricular Parasystole  
Monomorphic VT (Paroxysmal VT)  
Ventricular Escape Complexes and Idioventricular  
Rhythm  
Idiopathic VT  
Role of Programmed Electrical Stimulation  
Mechanisms of Ventricular Arrhythmias

**18 Torsade de Pointes, Ventricular Fibrillation, and Differential Diagnosis of Wide QRS Tachycardias 440**

Torsade de Pointes  
Ventricular Flutter and Fibrillation  
Commotio Cordis  
Differential Diagnosis of Tachycardia with Wide QRS  
Complex

**19 Atrioventricular Block; Concealed Conduction; Gap Phenomenon 456**

Atrioventricular Block  
Concealed Conduction  
Gap Phenomenon

**20 Ventricular Preexcitation (Wolff-Parkinson-White Syndrome and Its Variants) 481**

Wolff-Parkinson-White ECG Pattern  
Clinical Significance  
Tachyarrhythmias  
Anatomic Findings: Localization of the AP by Routine  
ECG  
Reentrant Tachycardia Associated with a Short PR  
Interval and Lown-Ganong-Levine Syndrome  
Mahaim-Type Preexcitation  
Ventricular Hypertrophy, BBB, and MI in the Presence  
of the WPW Pattern  
Effects of Drugs  
Radiofrequency Ablation of APs

**21 Effect of Drugs on the Electrocardiogram 509**

Antiarrhythmia Drugs  
Digitalis  
Miscellaneous Drugs

**22 Electrolytes, Temperature, Central Nervous System Diseases, and Miscellaneous Effects 532**

Electrolytes  
Temperature  
Miscellaneous Compounds  
Central Nervous System Diseases

**23 T Wave Abnormalities 555**

Secondary T Wave Abnormalities  
Primary T Wave Abnormalities  
Concomitant ST-T Abnormalities  
Nonspecific ST and T Abnormalities  
Computerized Analysis of T Wave Morphology and Spatial Orientation of the T Wave

**24 QT Interval, U Wave Abnormalities, and Cardiac Alternans 569**

QT Interval  
Abnormal U Wave  
Electrical Alternans

**25 Misplacement of Leads and Electrocardiographic Artifacts 586**

Misplacement of the Limb Lead  
Recognition of Lead Misplacement: Summary  
Artifacts

**26 Electrocardiography of Artificial Electronic Pacemakers 598**

BORYS SURAWICZ and LAWRENCE E. GERING

Pacemakers Components  
Pacemaker Nomenclature  
Pacemaker Stimulus Artifact  
Morphology of ECG Complexes  
Dual-Chamber Pacing  
Rate-Responsive Pacing  
Adaptive AV Delay, Rate Hysteresis, Fallback Response, Rate Smoothing, Rate-Responsive AV Delay, Mode Switching, Autocapture  
Pacing Failure  
ECG Signs of Malfunction of Ventricular Pacing  
ECG Signs of Malfunction of the AV Universal (DDD) Pacemakers  
Pacemaker Syndrome  
Ambulatory Monitoring in Patients with Pacemakers

**27 Ambulatory Electrocardiography 631**

Event Recorders  
Networking and Databases  
Ambulatory Recording in Normal Subjects  
Correlation with Symptoms of Palpitations, Dizziness, and Syncope  
Chest Pain  
Clues to the Arrhythmia Mechanism  
Patients with Specific Problems  
Heart Rate Variability

**Section II  
PEDIATRIC  
ELECTROCARDIOGRAPHY 647**

**28 Normal Electrocardiograms in the Fetus, Infants, and Children 647**

Heart Rate  
P Waves  
PR Interval  
QRS Complex: Morphology, Duration, and Axis  
Q Waves  
R Waves  
S Waves  
ST Segment  
T Waves  
QT Interval  
Indications for Performance of ECGs in Pediatrics

**29 Abnormal Electrocardiograms in the Fetus, Infants, and Children 658**

Atrial Abnormalities  
Ventricular Hypertrophy  
Ventricular Conduction Abnormalities  
QT Interval Prolongation  
Axis Deviation  
Abnormal Q Waves  
ST and T Abnormalities

**30 The Electrocardiogram in Congenital Heart Disease 671**

Acyanotic Lesions  
Cyanotic Lesions

**31 Cardiac Arrhythmias in the Fetus, Infants, Children, and Adolescents with Congenital Heart Disease 694**

Definitions  
Sinus Rhythms  
Atrial Arrhythmias  
AV Junctional Arrhythmias  
AV Reentrant Arrhythmias  
Ventricular Arrhythmias  
AV Block

**Index 721**