

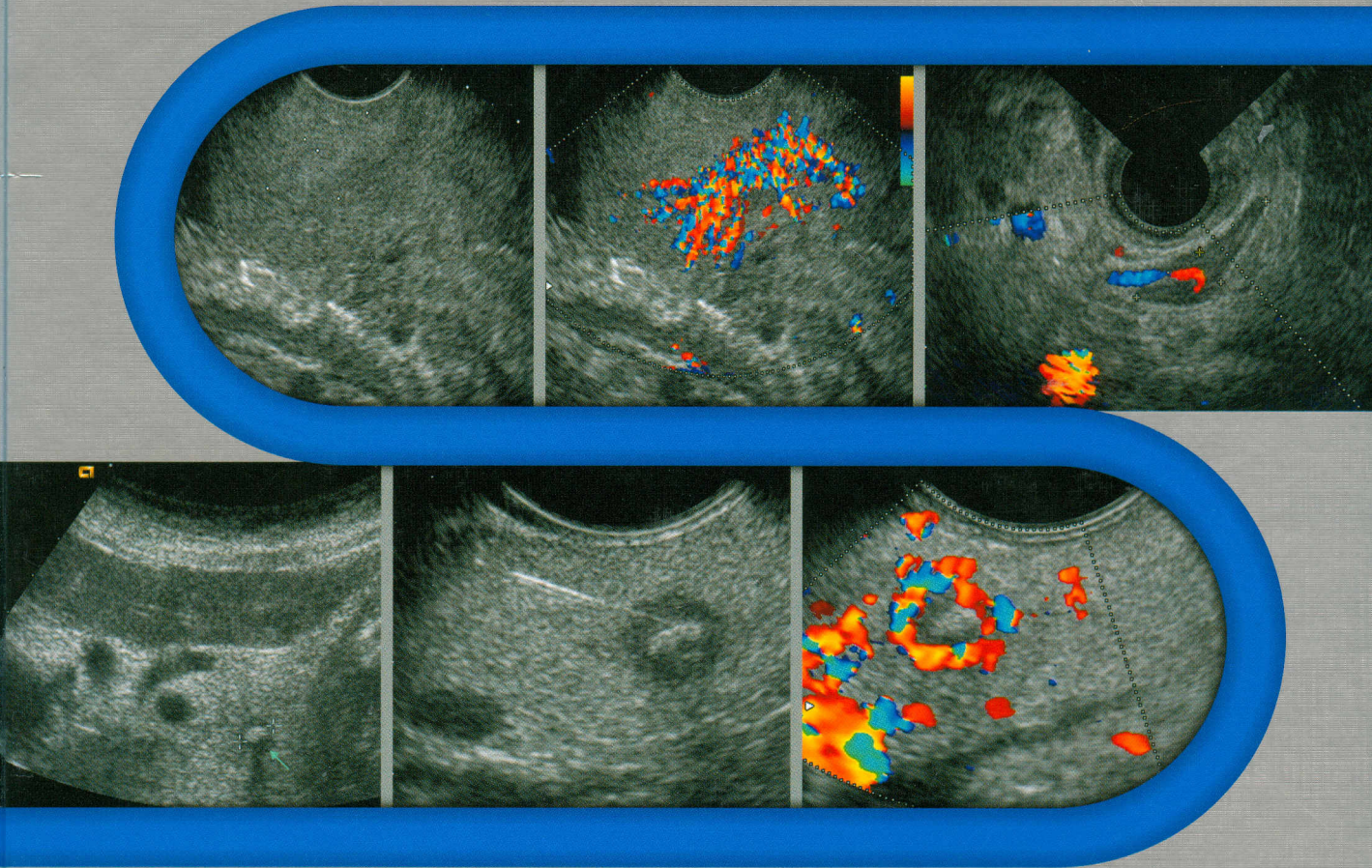
# Endoscopic Ultrasound

151441

An Introductory Manual and Atlas

Editor

Christoph Frank Dietrich





# Contents

<b>1 Basics of Radial Endoscopic Ultrasound</b> . . . 1	Examination of Structures Within and Adjacent to the Intestinal Wall. . . . . 24
<i>M. Hocke</i>	Extraductal Ultrasonography. . . . . 26
<b>Introduction</b> . . . . . 1	<b>Future Developments</b> . . . . . 26
<b>Ten Golden Rules</b> . . . . . 1	<b>Conclusions</b> . . . . . 26
Notes on the “Golden Rules” . . . . . 1	
<b>Patient Preparation</b> . . . . . 2	
<b>Examination Procedures</b> . . . . . 2	<b>5 Intraductal Ultrasound</b> . . . . . 27
Cross-Section of the Descending Duodenum. . . . . 2	<i>B. Braden, H. Seifert, C.F. Dietrich</i>
Cross-Section of the Papilla of Vater . . . . . 3	<b>Technical Developments</b> . . . . . 27
Cross-Section of the Duodenal Bulb . . . . . 3	<b>Intraductal Ultrasound of the Hepatobiliary System</b> . . . . . 27
Cross-Section of the Stomach . . . . . 4	Cholelithiasis. . . . . 28
Cross-Section of the Para-Aortic Region. . . . . 4	Bile Duct Strictures. . . . . 29
Cross-Section of the Adrenal Glands . . . . . 5	Cholangiocellular Carcinoma. . . . . 30
Cross-Section of the Lower Mediastinum . . . . . 5	<b>IDUS of the Pancreatic Ducts</b> . . . . . 33
Cross-Section of the Central Mediastinum . . . . . 5	<b>IDUS in Patients with Tumors of the Papilla and with Sphincter of Oddi Dysfunction</b> . . . . . 34
Cross-Section of the Upper Mediastinum . . . . . 5	<b>Conclusion</b> . . . . . 34
<b>Rating Levels of Skill in the Endoscopic Ultrasound Method</b> . . . . . 6	
	<b>6 Radial EUS, Linear EUS, or Ultrasound Miniprobe: Which Is the Most Suitable Device?</b> . . . . . 36
<b>2 Longitudinal EUS Anatomy</b> . . . . . 8	<i>J. Janssen, C.F. Dietrich</i>
<i>J. Janssen</i>	<b>The Development of EUS: a Short Historical Survey</b> . . . . . 36
<b>Introduction</b> . . . . . 8	<b>Miniprobe Versus Conventional EUS</b> . . . . . 37
<b>The Philosophy of the Examination</b> . . . . . 8	<b>Conventional Radial EUS Versus Conventional Longitudinal EUS</b> . . . . . 37
<b>EUS Landmarks</b> . . . . . 8	<b>Which Is the EUS Technique of the Future?</b> . . . . . 42
<b>The Examination Sequence</b> . . . . . 8	
<b>Special Linear EUS Anatomy</b> . . . . . 8	<b>7 Ultrasound Contrast Agents and Contrast-Enhanced Ultrasonography</b> . . . 44
EUS Anatomy Displayed from the Esophagus. . . . . 8	<i>C. Greis, C.F. Dietrich</i>
EUS Anatomy Imaged from the Stomach . . . . . 11	<b>Introduction</b> . . . . . 44
EUS Anatomy Imaged from the Duodenum. . . . . 13	<b>Historical Background</b> . . . . . 44
<b>Examination of the Gastrointestinal Wall</b> . . . . . 14	<b>Classification of Ultrasound Contrast Agents</b> . . . 45
<b>Conclusion</b> . . . . . 16	Blood Pool Contrast Agents . . . . . 45
	Tissue-Specific Contrast Agents. . . . . 45
<b>3 EUS meets VOXEL-MAN: a Computer-Based Training System for Longitudinal EUS</b> . . . 18	Drug-Delivery Systems . . . . . 45
<i>T. Leineweber, E. Burmester</i>	Intracavitary Contrast Agents . . . . . 45
<b>Introduction</b> . . . . . 18	Oral Contrast Agents. . . . . 45
<b>EUS meets VOXEL-MAN</b> . . . . . 19	<b>Mode of Action of Ultrasound Contrast Agents</b> 45
<b>Systematic Approach to an EUS Examination</b> . . . . . 20	Structure . . . . . 45
	Echogenic Properties. . . . . 46
<b>4 Miniprobes</b> . . . . . 23	Dosage and Administration . . . . . 46
<i>H. Seifert, C.F. Dietrich</i>	<b>Artifacts Caused by Contrast Agents</b> . . . . . 48
<b>Introduction</b> . . . . . 23	Saturation Artifacts. . . . . 48
<b>Technical Considerations and Practical Remarks</b> . . . . . 23	
<b>Miniprobe Applications in the Gastrointestinal Tract</b> . . . . . 24	

Destruction Artifacts . . . . .	48	<b>Research Results</b> . . . . .	67
Shadow Artifacts . . . . .	48	<b>Sonoelastography in the Clinical Setting</b> . . . . .	69
Overestimated Flow Rates in Spectral Doppler . . . . .	48		
<b>Contrast-Specific Imaging Procedures</b> . . . . .	49	<b>10 EUS-Guided Biopsy: Equipment and Technique</b> . . . . .	71
Frequency Filter Procedures . . . . .	49	<i>H.W. Sudholt, P. Vilmann</i>	
Harmonic Power Doppler . . . . .	49	<b>Introduction</b> . . . . .	71
Pulse Summation Procedures . . . . .	49	<b>Endoscopes</b> . . . . .	71
Investigations at Very Low Insonation Power (Low-MI Imaging) . . . . .	51	<b>Biopsy Needles</b> . . . . .	72
Flash Echo Imaging . . . . .	52	<b>Examination Room</b> . . . . .	77
SAE Imaging . . . . .	52	<b>Preparation of the Patient</b> . . . . .	77
<b>Qualitative Evaluation</b> . . . . .	52	<b>Biopsy Procedure</b> . . . . .	77
Vascular Geometry . . . . .	52	<b>Preparing the Smear</b> . . . . .	80
Perfusion Abnormalities (Hyperperfusion/Hypoperfusion) . . . . .	53	<b>Limitations and Complications</b> . . . . .	80
<b>Quantitative Evaluation</b> . . . . .	53		
Bolus Kinetics . . . . .	53	<b>11 Tips and Tricks for Fine-Needle Puncture</b> 82	
Transit Time Analysis . . . . .	54	<i>T. Beyer, T. Topalidis</i>	
Replenishment Kinetics . . . . .	54	<b>Introduction</b> . . . . .	82
Depletion Kinetics . . . . .	54	<b>Definition of Fine-Needle Puncture</b> . . . . .	82
Parametric Imaging . . . . .	55	<b>Cytological Examination</b> . . . . .	82
<b>Clinical Indications for Contrast-Enhanced Ultrasonography</b> . . . . .	55	<b>Collection</b> . . . . .	83
Doppler Signal Enhancement (Vascular Flow) . . . . .	55	<b>Specimen Handling</b> . . . . .	83
Diagnosis of Ischemia . . . . .	55	<b>Fixation</b> . . . . .	83
Diagnosis of Traumatic Lesions . . . . .	55	<b>Staining</b> . . . . .	85
Detection of Focal Lesions . . . . .	55	<b>Request Form, Clinical Data, Questions of Interest</b> . . . . .	85
Characterization of Focal Lesions . . . . .	56	<b>Causes of Errors in Fine-Needle Aspiration Biopsy</b> . . . . .	86
Monitoring of Interventions and Treatment Follow-Up . . . . .	56	<b>Capabilities and Limitations of Cytology</b> . . . . .	86
<b>Safety Aspects</b> . . . . .	57	<b>Standardized Documentation of Findings</b> . . . . .	86
<b>8 Three-Dimensional Linear Endoscopic Ultrasound</b> . . . . .	60		
<i>A. Fritscher-Ravens, H. Neye</i>		<b>12 Complications of Endoscopic Ultrasound: Risk Assessment and Prevention</b> . . . . .	87
<b>Introduction</b> . . . . .	60	<i>C. Jenssen, M. Mayr, D. Nürnberg</i>	
<b>Background</b> . . . . .	60	<b>EUS-Specific Factors Contributing to the Risk of Complications</b> . . . . .	87
<b>Technical Considerations</b> . . . . .	61	<b>Complications of Diagnostic EUS</b> . . . . .	87
<b>Transformation Methods</b> . . . . .	61	Perforation . . . . .	87
Parallel Guidance of the Transducer . . . . .	61	Aspiration . . . . .	88
Rotation . . . . .	61	Bacteremia . . . . .	89
Freehand Ultrasound . . . . .	61	<b>Complications with EUS-FNA and EUS-Guided Interventions</b> . . . . .	89
<b>Current Methods for Linear 3D Endoscopic Ultrasound</b> . . . . .	62	Bacteremia and Infectious Complications . . . . .	89
<b>3D EUS Examination in Patients</b> . . . . .	63	Bile Peritonitis and Cholangitis . . . . .	90
<b>Conclusion</b> . . . . .	64	Acute Pancreatitis . . . . .	90
		Hemorrhage . . . . .	90
<b>9 Sonoelastography: a New Ultrasound Modality for Assessing Tissue Elasticity</b> . . . . .	65	Tumor Cell Seeding . . . . .	93
<i>H. Frey, C.F. Dietrich</i>		<b>Prevention of EUS-Related Complications</b> . . . . .	93
<b>Introduction</b> . . . . .	65	Suggested Ways of Preventing Complications . . . . .	93
<b>Technical Characteristics</b> . . . . .	65	<b>Summary: Morbidity and Mortality of EUS and EUS-FNA</b> . . . . .	96

<b>13 Esophagus, Stomach, Duodenum</b> . . . . .	100	<b>15 Endosonographic Diagnosis and Treatment Planning in Gastrointestinal Lymphoma</b> . . . . .	155
<i>C.F. Dietrich, S. Faiss</i>		<i>W. Fischbach</i>	
<b>Introduction</b> . . . . .	100	<b>Introduction</b> . . . . .	155
<b>Esophagus</b> . . . . .	101	<b>Clinical Presentation</b> . . . . .	155
Orientation . . . . .	101	<b>Diagnosis and Staging</b> . . . . .	155
Optimizing the Examination. . . . .	101	<b>Relevance of EUS</b> . . . . .	156
Indications. . . . .	101	<b>Treatment Planning</b> . . . . .	159
Benign Diseases . . . . .	102		
Malignant Tumors of the Esophagus . . . . .	102		
T Stage. . . . .	104		
N Stage . . . . .	105		
Fine-Needle Aspiration . . . . .	105		
<b>Stomach</b> . . . . .	109	<b>16 Endoscopic Ultrasound in Chronic Pancreatitis</b> . . . . .	161
Orientation . . . . .	109	<i>C. Jenssen, C.F. Dietrich</i>	
Optimizing the Examination. . . . .	109	<b>Difficulties in Diagnosing Chronic Pancreatitis</b> .	161
Indications. . . . .	110	<b>Endosonography of the Pancreas</b> . . . . .	162
Benign Gastric Lesions . . . . .	110	<b>Endosonographic Criteria for Chronic Pancreatitis</b> . . . . .	165
Gastric Cancer . . . . .	112	<b>Comparison of Methods: Is EUS More Sensitive than ERCP for Diagnosing Chronic Pancreatitis?</b>	167
Review of the Literature . . . . .	113	Pitfalls . . . . .	169
<b>Small Bowel</b> . . . . .	118	<b>Endosonographic Staging of Chronic Pancreatitis</b> . . . . .	171
		<b>Diagnosis of Complications of Chronic Pancreatitis</b> . . . . .	171
<b>14 Endoscopic Ultrasound in Subepithelial Tumors of the Gastrointestinal Tract</b> . .	121	<b>Etiological Information</b> . . . . .	171
<i>C. Jenssen, C.F. Dietrich</i>		Practical Hints . . . . .	179
<b>Subepithelial Tumors versus Extramural Impressions (Lesions Mimicking Subepithelial Tumors)</b> . . . . .	122	<b>Differential Diagnosis, Diagnostic Problems, and Pitfalls</b> . . . . .	179
Pitfalls . . . . .	125	Pancreatic Cancer versus Focal Inflammatory Masses . . . . .	179
<b>Endosonographic Description and Classification of Subepithelial Lesions</b> . . . . .	126	Pseudocyst versus Simple Cyst versus Cystic Neoplasia versus Pseudoaneurysm . . . . .	183
Practical Hints . . . . .	126	Dilation of the Main Pancreatic Duct. . . . .	185
Pitfalls . . . . .	128	<b>The Contribution of EUS to the Treatment of Chronic Pancreatitis</b> . . . . .	187
<b>Cystic and Solid Cystic Subepithelial Lesions</b> . .	129	Pitfalls . . . . .	189
<b>Solid Subepithelial Lesions</b> . . . . .	132	Practical Hints . . . . .	189
Pitfalls . . . . .	135	<b>Conclusions</b> . . . . .	190
Practical Hints . . . . .	136		
Hypochoic Subepithelial Tumors of the Esophagus. . . . .	136	<b>17 Pancreatic Adenocarcinoma: the Role of Endoscopic Ultrasonography</b> . . . . .	196
Hypochoic Subepithelial Tumors of the Stomach	137	<i>P.G. Arcidiacono, S. Carrara</i>	
Hypochoic Subepithelial Tumors of the Duodenum . . . . .	138	<b>Introduction</b> . . . . .	196
Hypochoic Subepithelial Tumors of the Colon and Rectum. . . . .	139	<b>Principles of the Technique</b> . . . . .	197
<b>Assessment of the Biological Behavior of Hypochoic Subepithelial Tumors</b> . . . . .	141	<b>Staging</b> . . . . .	200
Pitfalls . . . . .	143	<b>EUS-FNA Technique</b> . . . . .	204
<b>EUS-Guided Fine-Needle Aspiration</b> . . . . .	144		
<b>EUS-Guided Treatment of Subepithelial Lesions</b> . . . . .	145	<b>18 Benign and Malignant (Cystic) Tumors of the Pancreas</b> . . . . .	208
Pitfalls and Practical Hints . . . . .	145	<i>C.F. Dietrich, C. Jenssen</i>	
<b>Diagnostic and Therapeutic Strategy for Subepithelial Lesions in the Gastrointestinal Tract</b> . .	147	<b>Introduction</b> . . . . .	208



<b>Cystic Neoplasms</b> . . . . .	209	<b>22 Contrast-Enhanced EUS in the Pancreas</b> . . . . .	273
Mucinous Cystadenoma and Cystadenocarcinoma	210	<i>M. Hocke, C.F. Dietrich</i>	
Intraductal Papillary Mucinous Neoplasm (Mucinous Duct Ectasia) . . . . .	210	<b>Detection</b> . . . . .	273
Serous Cystadenoma . . . . .	212	<b>Characterization of Malignancy</b> . . . . .	273
Papillary Cystic Neoplasm (Solid Pseudopapillary Neoplasm) . . . . .	215	Review of the Literature [1] . . . . .	274
Teratoma of the Pancreas . . . . .	216	<b>Wide-Band Harmonic Imaging</b> . . . . .	277
Rare Cystic Neoplasms and Miscellaneous		<b>Lymph Nodes</b> . . . . .	277
Pancreatic Lesions Mimicking Cystic Neoplasms . . . . .	216	<b>Prospects</b> . . . . .	281
<b>Neuroendocrine Tumors</b> . . . . .	222	<b>23 Incidental Findings in the Surrounding Organs (Miscellaneous)</b> . . . . .	282
<b>19 Pancreatic Interventions</b> . . . . .	230	<i>C.F. Dietrich</i>	
<i>H. Seifert, C.F. Dietrich</i>		<b>Introduction</b> . . . . .	282
<b>Introduction</b> . . . . .	230	<b>24 Endoanal and Endorectal Sonography</b> . . . . .	291
<b>Cystic Pancreatic Lesions: Definition and Classification</b> . . . . .	230	<i>M. Sailer, H. Allgayer, C.F. Dietrich</i>	
<b>Epidemiology</b> . . . . .	233	<b>Introduction</b> . . . . .	291
<b>Etiopathogenesis</b> . . . . .	234	<b>Normal Anatomy</b> . . . . .	291
<b>Therapeutic Approaches</b> . . . . .	234	Anatomy of the Perineum and Anus . . . . .	291
Objectives of Treatment . . . . .	234	Endosonographic Imaging at Different Anatomical Levels . . . . .	296
Spontaneous Course . . . . .	235	<b>Instruments and Equipment</b> . . . . .	297
Conservative Treatment . . . . .	236	<b>Clinical Indications for Endorectal Ultrasound Techniques</b> . . . . .	297
Interventional Treatment . . . . .	236	Rectal Cancer . . . . .	298
<b>Summary and Prospects</b> . . . . .	247	Tumor Staging . . . . .	298
<b>20 Endosonography of the Hepatobiliary System</b> . . . . .	251	<b>Preoperative Diagnosis of Rectal Carcinomas</b> . . . . .	304
<i>C.F. Dietrich, M. Hocke, H. Seifert</i>		<b>Tumor Follow-Up</b> . . . . .	305
<b>Definitions</b> . . . . .	251	<b>Anorectal Endosonography in Fecal Incontinence</b> . . . . .	305
<b>Reliability of Examination Methods for Detecting Gallstones</b> . . . . .	251	Anal Fistula . . . . .	306
<b>Miniprobe EUS and Extraductal Ultrasound</b> . . . . .	255	<b>Interventional Procedures with Endoscopic Anorectal Ultrasound</b> . . . . .	307
<b>Adenoma and Carcinoma of the Papilla of Vater</b> . . . . .	256	EUS-Guided Transrectal Biopsies of Pelvic Tumors . . . . .	307
<b>EUS of the Papillary Region, Adenomyomatosis</b> . . . . .	257	EUS-Guided Transrectal Aspiration of Pelvic Fluid Collections . . . . .	308
<b>Cholangiocellular Carcinomas</b> . . . . .	258	Anal Cancer . . . . .	309
<b>Carcinomas of the Gallbladder</b> . . . . .	259	Perineal Transcutaneous Ultrasound . . . . .	310
<b>Conclusions</b> . . . . .	259	<b>25 Three-Dimensional Endorectal Ultrasound (ERUS) and Rectal Cancer</b> . . . . .	313
<b>21 Endoscopic Ultrasound Imaging of the Adrenals</b> . . . . .	264	<i>M. Giovannini</i>	
<i>C.F. Dietrich, P.H. Kann</i>		<b>Introduction</b> . . . . .	313
<b>Introduction</b> . . . . .	264	<b>Basic Principles of 3D Ultrasound</b> . . . . .	313
<b>Examination Technique</b> . . . . .	264	<b>Results of 3D ERUS in the Literature</b> . . . . .	313
Transabdominal Examination Technique . . . . .	264	<b>Conclusions</b> . . . . .	316
Endoscopic Ultrasound Examination Technique . . . . .	264	<b>26 Endoscopic Ultrasound of the Colon</b> . . . . .	317
<b>Indications for EUS of the Adrenal Glands</b> . . . . .	266	<i>C.F. Dietrich, J. Mertens</i>	
<b>Pathological Findings</b> . . . . .	266	<b>Introduction</b> . . . . .	317
<b>Conclusion and Summary</b> . . . . .	271	<b>Clinical Relevance</b> . . . . .	317

<b>27 Mediastinum</b> . . . . .	323	<b>Indications for Therapeutic EUS</b> . . . . .	354
<i>C.F. Dietrich, M. Hocke</i>		<b>Contraindications to Therapeutic EUS</b> . . . . .	354
<b>Introduction</b> . . . . .	323	<b>Materials</b> . . . . .	354
<b>Anatomy</b> . . . . .	323	Echoendoscopes . . . . .	354
<b>Examination Techniques</b> . . . . .	324	Materials for Therapeutic EUS Procedures . . . . .	355
General . . . . .	324	<b>Celiac Plexus Neurolysis</b> . . . . .	356
Procedure . . . . .	325	Preparation for the Procedure . . . . .	356
<b>Literature Review</b> . . . . .	327	Procedure . . . . .	357
EUS-Guided Fine-Needle Aspiration in the		Problems and Complications . . . . .	358
Mediastinum . . . . .	327	Postinterventional Measures . . . . .	359
Non-Small-Cell Lung Cancer . . . . .	328		
<b>Prospects and Limitations</b> . . . . .	331	<b>31 EUS-Guided Bile Duct Drainage</b> . . . . .	360
<b>Conclusions</b> . . . . .	332	<i>E. Burmester, J. Niehaus</i>	
		<b>Introduction</b> . . . . .	360
<b>28 Endobronchial Ultrasound with</b>		<b>Technique</b> . . . . .	360
<b>Miniprobe Radial Scanning</b> . . . . .	334	<b>Results</b> . . . . .	361
<i>H.D. Becker</i>		<b>Conclusions</b> . . . . .	362
<b>Introduction</b> . . . . .	334		
<b>Miniprobes: General Considerations</b> . . . . .	334	<b>32 Laparoscopic Ultrasound Scanning</b> . . . . .	364
<b>Handling of Miniprobes</b> . . . . .	334	<i>P. Vilmann, C. Ortiz-Moyano</i>	
Storage and Preparation . . . . .	334	<b>Introduction</b> . . . . .	364
Application . . . . .	335	<b>Equipment</b> . . . . .	364
<b>Technique of EBUS</b> . . . . .	335	<b>Examination Procedure</b> . . . . .	366
Imaging Artifacts . . . . .	335	<b>Biopsy Procedure</b> . . . . .	369
Sonographic Anatomy . . . . .	335	<b>Review of the Literature</b> . . . . .	371
<b>Clinical Results</b> . . . . .	337	Staging of Gastrointestinal Cancers . . . . .	371
<b>Staging of Lung Cancer</b> . . . . .	338	LUS in Esophagogastric Cancer . . . . .	371
<b>EBUS in Therapeutic Bronchoscopy</b> . . . . .	343	LUS in Pancreatic Cancer . . . . .	371
<b>EBUS in Pediatric Bronchoscopy</b> . . . . .	343	LUS in Colonic Cancer . . . . .	372
<b>Training and Learning Curve in EBUS</b> . . . . .	343	LUS in Gallstone Disease . . . . .	372
<b>Cost-Effectiveness</b> . . . . .	344	LUS in Liver Disease . . . . .	373
<b>Conclusions and Future Prospects</b> . . . . .	344	Miscellaneous Applications of LUS . . . . .	374
		LUS-Guided Therapy . . . . .	374
<b>29 Endobronchial Ultrasound</b> . . . . .	347		
<i>F.J.F. Herth, R. Eberhardt, M. Krasnik, P. Vilmann</i>		<b>33 EUS-Guided Endosurgery</b> . . . . .	378
<b>Introduction</b> . . . . .	347	<i>A. Fritscher-Ravens</i>	
<b>Lymph-Node Staging</b> . . . . .	347	<b>Introduction</b> . . . . .	378
<b>Description of the EBUS-TBNA Endoscope and</b>		<b>New Devices</b> . . . . .	378
<b>Needle</b> . . . . .	347	Suturing System . . . . .	378
<b>Procedure</b> . . . . .	348	EUS-Guided Snare Resection System . . . . .	380
<b>Results</b> . . . . .	349	<b>EUS-Guided Therapy</b> . . . . .	380
<b>EBUS-TBNA in Combination with EUS-FNA</b> . . . . .	350	Closing Fistulas . . . . .	380
<b>Conclusion</b> . . . . .	350	Transgastric Anastomosis . . . . .	381
		EUS-Guided Posterior Gastropexy for Reflux	
<b>30 EUS-Guided Neurolysis of the Celiac</b>		Disease . . . . .	383
<b>Plexus</b> . . . . .	352	EUS-Guided Lymph-Node Removal . . . . .	384
<i>S. Hollerbach</i>		<b>Conclusion</b> . . . . .	385
<b>Introduction</b> . . . . .	352		
<b>Prerequisites for EUS-Guided Celiac Plexus</b>		<b>34 Index</b> . . . . .	387
<b>Neurolysis and Other Treatments</b> . . . . .	353		